

Open Distal Ureterectomy and Boari Flap Reconstruction for Distal Ureteric Transitional Cell Carcinoma

Robinson S*, Parnham A and Motiwala H

Department of Urology, Frimley Health Foundation Trust, UK

Article Information

Received date: Oct 06, 2017

Accepted date: Nov 29, 2017

Published date: Dec 01, 2017

*Corresponding author

Robinson S, Department of Urology,
Frimley Health Foundation Trust,
Wexham street slough east berkshire
SL24HL, United Kingdom,
Tel: +79 81 323-750;
Email: simon.robinson@fhft.nhs.uk

Distributed under Creative Commons
CC-BY 4.0

Abstract

The standard surgical treatment of distal ureteric transitional cell carcinoma remains nephroureterectomy with excision of a cuff of bladder. We present a series of 20 patients who were managed with open distal ureterectomy and Boari flap reconstruction.

Objective: To study the suitability of open distal ureterectomy and Boari flap reconstruction in the management of distal ureteric TCC.

Methods: Data was collected retrospectively on one consultant's patients, operated on between 2004-2015.

Results: We treated 20 patients with a mean age of 71 years (55-88 years). There were thirteen males and seven females. Six tumours were on the right and fourteen on the left. The mean follow up was 79 months (6.5 years) (8-144 months) with three recurrences (2 ureteric, 1 renal pelvis). There has been only one complication.

Conclusion: Upper urinary tract tumours are rare. Radical nephroureterectomy with excision of bladder cuff may over treat this disease compromising renal function unnecessarily. In selected cases open distal ureterectomy and Boari flap reconstruction may be considered.

Introduction

Transitional cell carcinoma of the ureter is a relatively uncommon condition contributing to less than 5% of all urothelial cancers with the majority (70%) occur in the lower ureter *versus* 25% in the mid ureter and 5% in the upper ureter [1,2]. This pattern of distribution is thought to be attributed to downstream implantation.

A propensity to multifocality and recurrence in the ipsilateral ureter, as well as a low recurrence rate in the contralateral ureter, make radical nephroureterectomy the logical Gold standard treatment [3-8]. However some patients are inherently unsuitable for nephroureterectomy; such as those with a functionally solitary kidney, renal insufficiency or multiple co-morbidities. Nephroureterectomy would impose upon these individuals the need for dialysis, or have a profound effect upon quality of life and life expectancy [9]. Furthermore patients and clinicians often hesitate at nephroureterectomy in those with low grade, unilateral tumours in the distal ureter.

In response to the difficulty posed by patients deemed unsuitable for nephroureterectomy, there have been a number of attempts to manage this condition with renal sparing and less invasive techniques including endoscopic control (for example laser ablation), or segmental ureterectomy with ureter-ureteric anastomosis. However local excision preserves the ureter distal to the primary tumour where recurrence is most common up to 50% [10]. Distal ureterectomy would theoretically reduce the risk of these distal recurrences.

In our institution the patient is placed in supine position and prepared to include the genitalia to enable catheterisation during surgery. A curvilinear Rutherford-Morris or Gibson incision is made on the affected side allowing access to the bladder and affected ureter. The ureter is then isolated as it crosses the common iliac at the pelvic brim and mobilised along its entire length. The urachus is divided and an inverted U shaped anterior peritoneotomy is made to mobilise the anterior and anterolateral aspects of the bladder in the retropubic space [11]. The bladder is then filled with saline. An anterolateral bladder flap based on the ipsilateral vesical pedicle is created in a 'boot' shape. The flap should be three to four centimetres longer than the defect. The affected ureter then has a standard JJ stent inserted retrograde, if one has not already been placed, and tied into the ureteric orifice with suture. The Ureteric orifice and ureter is then excised in continuity as a cuff. The proximal ureter is excised as high as possible over the stent, and a refluxing ureteroneocystostomy is created. It is our belief that this allows easier visualisation of the proximal ureter for future follow up of these patients. Mucosa to mucosa absorbable stitches are placed between the spatulated free proximal ureter and the bladder mucosa. A new JJ stent is then placed and the Boari flap tubularised in two layers. A drain is then placed in the pelvis and the abdominal wound closed as per normal.

We present a series of patients with bulky low grade distal ureteric carcinoma, managed with distal ureterectomy and Boari flap reconstruction.

Methods

A retrospective database was collected on all patients at a single hospital who had open distal ureterectomy and Boari flap reconstruction for distal ureteric transitional cell carcinoma by one surgeon. This was to replace the lower ureter in its entirety and allow tension free anastomosis.

Patients were identified using the National Health Service OPCS Classification version 4.5 unique code for distal ureterectomy, Boari flap reconstruction and ureteric reimplantation. The tumours were all distal near the bladder end and up to the pelvic brim keeping 2cm proximal margin free. The majority of tumours were 2-4cm, two were 6cm.

A retrospective review of the patient notes and investigations was made. Data was collected on patient demographics, presenting symptoms, risk factors, pre-operative co-morbidities, pre-operative estimated Glomerular Filtration Rate (eGFR), histology, recurrence and complications using Microsoft Excel 2007.

Results

Data was collected on 20 consecutive patients between 2004 and 2015 that had distal ureterectomy and Boari flap reconstruction for distal ureteric transitional cell carcinoma. The patient summary demographics, are listed in table 1. Specific patient demographics are in table 2. The histology of diagnostic biopsy, final specimen and progression and survival figures are in table 3 and 4. None of the patients were censored. Two patients died from the cancer and eight died overall. Three showed recurrence. One developed a new tumour in the other ureter.

The majority of patients presented with haematuria, 55% (11/20), 25% (5/20) were detected with bladder tumour surveillance and 20% were incidental findings (4/20). The mean length of ureter resected was 83mm. Ten patients had G2pTa, six had G1pTa, one patient had

Table 1: Summary values of patients.

Male/female	13/7
Age	Mean 71 (sd±11) median 72
Side left/right	14 left/ 6 right
Length of distal ureter	Mean 83mm (sd±30)
Creatinine pre op	Mean 101µM (sd±58)
post op	Mean 104 µM (sd±60)
Mann Whitney P	P = 0.8
eGFR pre op	Mean 70ml/min/1.73m ² (sd±20)
post op	Mean 66ml/min/1.43m ² (sd±20)
Mann Whitney P	P = 0.7
Presentation Haematuria	11
Surveillance	5
Incidental	4

G2pT1 and three had G3pT2 disease. The mean length of follow up was 79 months (8-144 months).

Five biopsies were upgraded/staged. Three G1pTa biopsies subsequently proved to have G2pTa disease. One G3pT1 biopsy was upstaged to G3pT2 and one biopsy that showed inflammatory changes only proved to have G3pT2 disease (Graph).

Local recurrence

There were three cases of local recurrence. Three were ipsilateral ureteric tumours and one new contralateral tumour. All three high grade cases developed recurrence.

The first ureteric local recurrence (patient 1) was G1pTa and subsequently underwent radical nephroureterectomy. This was at 54 months.

The second ureteric local recurrence (patient 2) was G2pTa low grade, (34mm from the distal ureteric margin). This patient consequently had a nephroureterectomy and no further recurrence. The third (patient 19) had a contralateral recurrence that was offered a nephroureterectomy but she opted for a laser ablation. The fourth (patient 20) developed an ipsilateral recurrence within the renal pelvis and died.

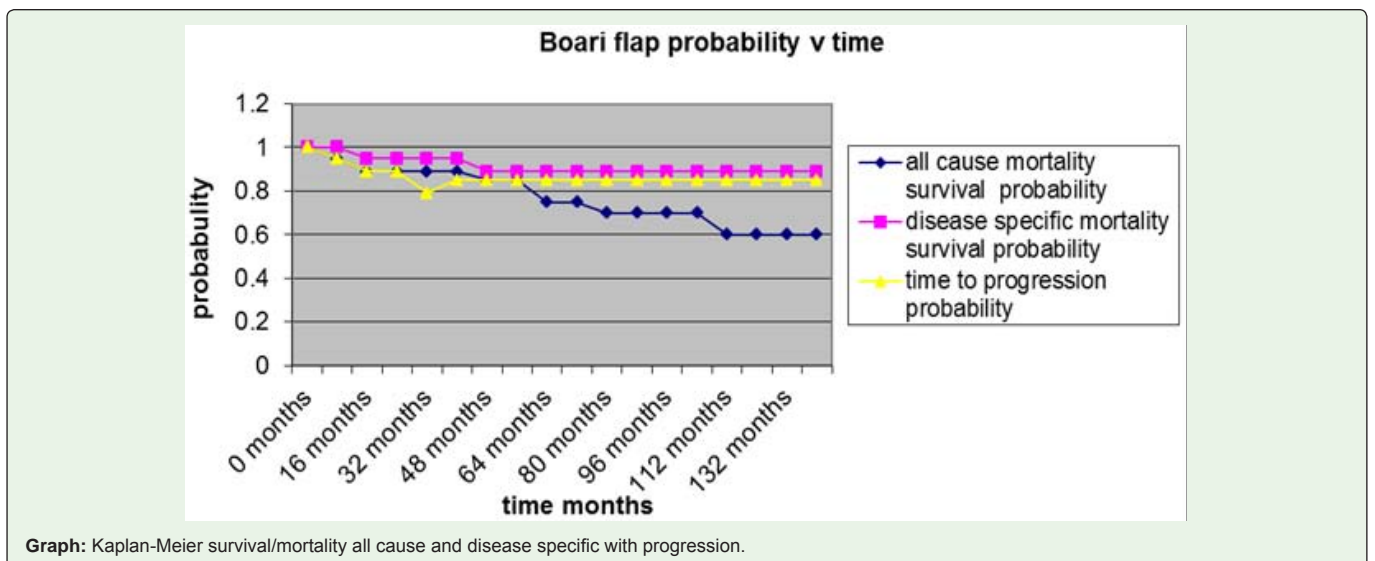


Table 2: Basic patient characteristics.

Patient number	ASA	Age	Side	Smoker	Presentation	eGFR ml/min/1.73m ²	Creatinine (µM)	CKD
1	1	64	Right	Yes	Haematuria	72	75	2
2	2	85	Left	No	Surveillance	53	92	2
3	3	75	Left	No	Haematuria	62	83	2
4	1	69	Left	Yes	Surveillance	56	91	3
5	2	61	Left	Yes	Surveillance	65	82	3
6	2	55	Right	Yes	Incidental	86	85	2
7	2	63	Right	No	Surveillance	77	91	3
8	2	78	Right	Yes	Haematuria	60	110	3
9	2	82	Left	Yes	Incidental	62	105	3
10	2	55	Left	Yes	Haematuria	90	82	2
11	3	78	Left	No	Incidental	16	339	4
12	2	68	Left	Yes	Haematuria	86	82	1
13	2	81	Left	Yes	Haematuria	82	83	1
14	1	56	Left	Yes	Haematuria	99	75	1
15	2	77	Left	Yes	Haematuria	55	119	2
16	3	88	Left	Ye	Surveillance	48	129	3
17	3	81	Left	No	Haematuria	89	77	1
18	1	69	Left	Yes	Incidental	89	70	1
19	1	57	Right	No	Haematuria	89	67	1
20	3	87	Right	No	Haematuria	58	80	3

Table 3: Biopsy, operative histology and outcomes.

Patient	Biopsy	Final histology	Recurrence	All cause mortality	Disease specific mortality
1	G1pTa	G2pTa	G1pTa ipsilateral ureter	No	No
2		G1pTa	G2pTa ipsilateral ureter	yes	No
3	G1pTa	G1pTa		Yes	No
4		G2pTa		No	No
5	G1pTa	G1pTa		No	No
6	Malignant?	G1pTa		No	No
7	G2pTa	G2pTa		No	No
8	G1pTa	G2pTa		No	No
9	G1pTa	G2pTa		Yes	No
10	G1pTa	G1pTa		No	No
11	G2pT1	G2pT1		Yes	No
12		G2pTa		No	No
13	G2pTa	G2pTa		Yes	No
14	G2pTa	G2pTa		No	No
15		G2pTa		Yes	No
16		G2pTa		No	No
17		G3pT2		Yes	Yes
18	G3pT1	G3pT2		No	No
19		G1pTa	G2pTa contralateral ureter	No	No
20	Inflammation	G3pT2	Ipsilateral Pelvic	yes	Yes

Table 4: Summary outcomes.

	Number of patients	5 year % survival
Time to progression	3 (3 ureteric, 1 pelvic)	85% (17 showed no progression)
Disease specific survival	2	90% survival (2 RIP)
All cause survival	8	60% survival (8 RIP)

There were three patients (17, 18 and 20) who had high grade muscle invasive disease. Patient 17 had numerous co-morbidities, obesity, diabetes, COPD, colon cancer and bladder cancer. His ASA was 3. Patient 20 had a biopsy that showed inflammatory changes only and suffered from CKD stage 3 and had an ASA of 3. The patients were offered both radical nephro-ureterectomy or distal ureterectomy and Boari flap but opted for the latter. Patient 18 developed a high grade bladder recurrence and subsequently underwent radical cystoprostatectomy.

Overall there was no significant change in the mean postoperative MDRD eGFR (66ml/min vs 70ml/min P =0.7) or in the serum creatinine (104 µM vs 101µM P =0.8).

Although there were a number of minor complications there was only one case of note of testicular atrophy.

Discussion

The incidence of upper urinary tract urothelial tumours is accepted to be approximately 1-2 new cases per 105 of the population per year, although data from the Surveillance, Epidemiology and End Results (SEER) database demonstrates an increase in ureteric tumours from 0.69 to 0.73 per 100,000 person-years between 1973 and 1996 [10,12].

Ureteric tumours occur more commonly in the lower than the upper ureter. Overall, about 70% of ureteric tumours occur in the distal ureter, 25% in the mid-ureter, and 5% in the proximal ureter [1]. This pattern of distribution is thought to be due to downstream implantation.

Although the standard treatment for distal ureteric transitional cell carcinoma has been nephroureterectomy this approach has significant postoperative morbidity and mortality [13,14]. The fact

that ureteric tumours tend to occur in older patients, who now have a longer life expectancy, and the finding that with ageing there are increased risks for renal deterioration resulting from nephrosclerosis, atherosclerosis, diabetes mellitus etc, only strengthens the need for preservation of renal function and nephrons sparing surgery [15].

There have been a number of attempts to manage these patients with different strategies ranging from laparoscopic surgery to endoscopic control with varying degrees of success. Recent reports have demonstrated the feasibility of such techniques including endoscopic and percutaneous control. However the recurrence rate in the ipsilateral unit can be as high as 23-54% and cause specific mortality between 11-18% [16-28]. We feel that distal ureterectomy and Boari flap reconstruction is an improvement upon standard approaches for patients that require renal sparing surgery with isolated low grade disease at the distal ureter. It represents a more considered approach that respects the natural history of the disease and adheres to the principles required for controlling the disease. However, patient choice may dictate the decision to avoid radical nephroureterectomy.

Our patients were followed up rigorously with intravenous pyelogram, cystoscopy and ureterorenoscopy with urine cytology and upper tract cytology at three months and then six monthly for two years. For those patients whose co-morbidity precludes them from this intensive regime the time scale is adhered to but investigation includes computed tomography urogram and cytology.

The major difference between nephroureterectomy and local excision is ipsilateral recurrence which ranges from 4.8-40% [1,15,29-33]. Although most ipsilateral recurrences occur distal to the site of the original tumour, regardless of stage or grade, occasional proximal recurrences are found [10,15]. Our series compares favourably with these quoted figures (Figures 1, 2 & 3).

Regarding oncological outcomes after conservative treatments we note that there is evidence that distal ureterectomy is as effective and safe as radical nephroureterectomy in terms of cancer specific survival, recurrence free survival and metastasis free survival [34]. Other studies showed no difference in overall survival, cancer specific survival and intravesical recurrence free survival [35-37]. Neither is there any significant deterioration in renal function post operatively similar to a multi-institutional study comparing radical and conservative surgeries [38].

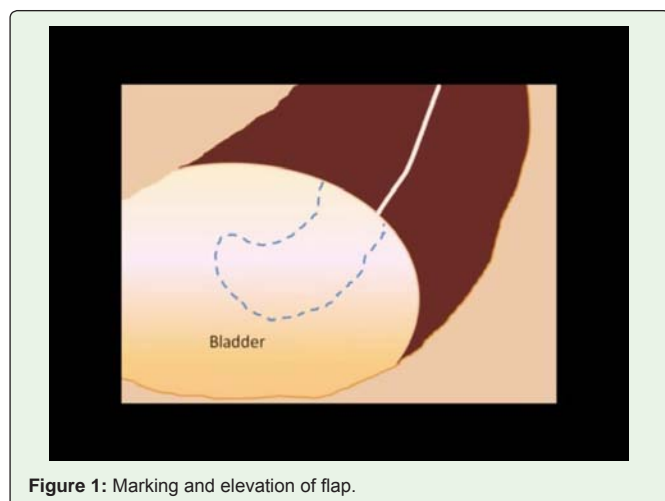


Figure 1: Marking and elevation of flap.

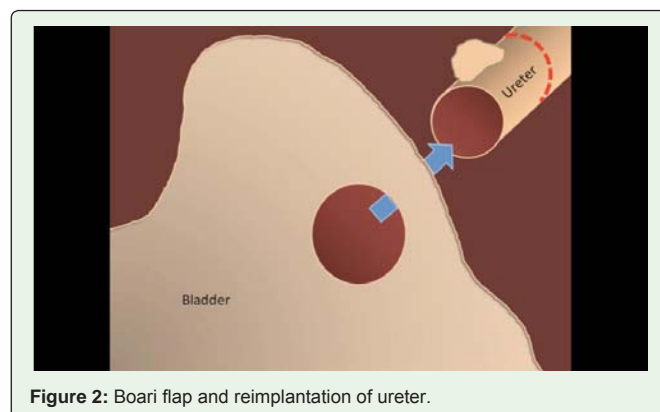


Figure 2: Boari flap and reimplantation of ureter.

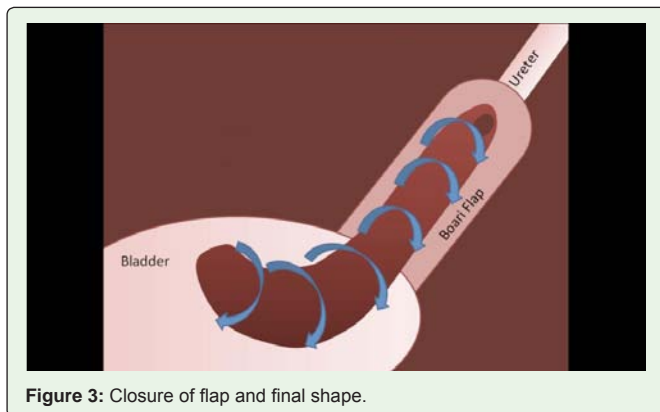


Figure 3: Closure of flap and final shape.

In excising the distal ureteric transitional cell carcinoma in continuity we also take a larger than normal segment of proximal ureter as well as completely excising the distal ureter and ureteric orifice. A standard Boari flap enables us to make up this substantial defect where a psoas hitch would be inadequate. This is reflected in the average length of ureter being 85 mm on histological specimen examination with a maximum of 15.5mm. We do a direct anastomosis where the ureter is wide and dilated. In a non-dilated ureter we prefer tunneling with anti-reflux anastomosis.

Conclusion

There are a group of patients who having developed an isolated distal ureteric transitional cell carcinoma are unsuitable for nephroureterectomy due to co-morbidity or the need to conserve nephrons. In such cases there are a number techniques, all of which by the comparative rarity of the disease have minimal evidence to recommend them. We suggest distal ureterectomy and Boari flap reconstruction in our series is at least comparable to these techniques. Accepting the limitations of this series the results appear favourable in our institute.

References

- Anderström C, Johansson SL, Pettersson S, Wahlqvist L. Carcinoma of the ureter: a clinicopathological study of 49 cases. *J Urol.* 1989; 142: 280-283.
- Landis SH, Murray T, Bolden S, Wingo PA. Cancer statistics 1999. *CA Cancer J Clin.* 1999; 49: 8-31.
- Charbit L, Gendreau MC, Mee S, Cukier J. Tumours of the upper urinary tract: 10 years of experience. *J Urol.* 1991; 146: 1243-1246.
- McCarron JP, Chasko SB, Gray GF. Systematic mapping of nephroureterectomy specimens removed for urothelial cancer: pathological findings and clinical correlations. *J Urol.* 1982; 128: 243-246.
- Strong DW, Pearse HD. Recurrent urothelial tumours following surgery for transitional cell carcinoma of the upper urinary tract. *Cancer.* 1976; 38: 2173-2183.
- Bloom NA, Vidone RA, Lytton B. Primary carcinoma of the ureter: a report of 102 new cases. *J Urol.* 1970; 103: 590-598.
- Zubac DP, Kihl B. Local excision of ureteral tumours. *Scand J Urol Nephrol.* 1997; 31: 435-438.
- Hall MC, Womack S, Sagalowsky AI, Carmody T, Erickstad MD, Roehrborn CG. Prognostic factors, recurrence, and survival in transitional cell carcinoma of the upper urinary tract: a 30-year experience in 252 patients. *Urology.* 1998; 52: 594-601.
- Held PJ, Brunner F, Odaka M, Garcia JR, Port FK, Gaylin DS. Five-year survival for end-stage renal disease patients in the United States, Europe, and Japan, 1982 to 1987. *Am J Kidney Dis.* 1990; 15: 451-457.
- Mazeman E. Tumours of the upper urinary tract calyces, renal pelvis and ureter. *Eur Urol.* 1976; 2: 120-126.
- Wein AJ, Kavoussi LR, Novick AC, Partin AW. *Campbell-Walsh Urology.* 9th edn. Philadelphia: Saunders. 2006.
- Jemal A, Tiwari RC, Murray T, Ghafoor A, Samuels A, Ward E, et al. *Cancer Statistics 2004.* *CA Cancer J Clin.* 2004; 54: 8-29.
- Gill IS, Sung GT, Hobart MG, Savage SJ, Meraney AM, Schweizer DK, et al. Laparoscopic nephroureterectomy for upper tract transitional cell carcinoma: the Cleveland Clinic experience. *J Urol.* 2000; 164: 1513-1522.
- Shalhav AL, Dunn MD, Portis AJ, Elbahnasy AM, McDougall EM, Clayman RV. Laparoscopic nephroureterectomy for upper tract transitional cell cancer: the Washington University Experience. *J Urol.* 2000; 163: 1100-1104.
- Johnson DE, Babaian RJ. Conservative management for non-invasive distal ureteral carcinoma. *Urology.* 1979; 13: 365-367.
- Martínez-Piñero JA, García Matres MJ, Martínez-Piñero L. Endourological treatment of upper tract urothelial carcinomas: analysis of a series of 59 tumours. *J Urol.* 1996; 156: 377-385.
- Clark PE, Streem SB, Geisinger MA. 13-year experience with percutaneous management of upper tract transitional cell carcinoma. *J Urol.* 1999; 161: 772-775.
- Chen GL, Bagley DH. Ureteroscopic management of upper tract transitional cell carcinoma in patients with normal contralateral kidneys. *J Urol.* 2000; 164: 1173-1176.
- Jabbour ME, Desgrandchamps F, Cazin S, Teillac P, Le Duc A, Smith AD. Percutaneous management of grade II upper urinary tract transitional cell carcinoma: the long term outcome. *J Urol.* 2000; 163: 1105-1107.
- Gerber GS, Lyon ES. Endourological management of upper tract urothelial tumours. *J Urol.* 1993; 150: 1-7.
- Elliott DS, Blute ML, Patterson DE, Bergstralh EJ, Segura JW. Long-term follow-up of endoscopically treated upper urinary tract transitional cell carcinoma. *Urology.* 1996; 47: 819-825.
- Patel A, Soonawalla P, Shepherd SF, Dearnaley DP, Kellett MJ, Woodhouse CR. Long-term outcome after percutaneous treatment of transitional cell carcinoma of the renal pelvis. *J Urol.* 1996; 155: 868-874.
- Deligne E, Colombel M, Badet L, Philippe T, Olivier R, Jean MD, et al. Conservative management of upper urinary tract tumours. *Eur Urol.* 2002; 42: 43-48.
- Goel MC, Mahendra V, Roberts JG. Percutaneous management of renal pelvic urothelial tumours: long-term follow up. *J Urol.* 2003; 169: 925-929.
- Djokic M, Hadzi-Djokic J, Nikolic J, Dragicevic D, Durutovic O, Radivojevic D. Tumours of the upper urinary tract: results of conservative surgery. *Prog Urol.* 2001; 11: 1231-1238.
- Iborra I, Solsona E, Casanova J, Ricós JV, Rubio J, Climent MA. Conservative elective treatment of upper urinary tract tumours: a multivariate analysis of prognostic factors for recurrence and progression. *J Urol.* 2003; 169: 82-85.
- Tawfik ER, Bagley DH. Upper- tract transitional cell carcinoma. *Urology.* 1997; 50: 321-329.
- Oosterlinck W, Solsona E, van der Meijden AP, et al. EAU guidelines on diagnosis and treatment of upper urinary tract transitional cell carcinoma. *Eur Urol.* 2004; 46: 147-154.
- Wallace DM, Wallace DM, Whitfield HN, Hendry WF, Wickham JE. The late results of conservative surgery for upper tract urothelial carcinomas. *Br J Urol.* 1981; 53: 537-541.
- Mufti GR, Gove JR, Badenoch DF. Transitional cell carcinoma of the renal pelvis and ureter. *Br J Urol.* 1989; 63: 135-140.

31. Zoretic S, Gonzales J. Primary carcinoma of ureters. *Urology*. 1983; 21: 354-356.
32. Murphy DM, Zincke H, Furlow WL. Management of high grade transitional cell cancer of the upper urinary tract. *J Urol*. 1981; 125: 25-29.
33. Bazeed MA, Schärfe T, Becht E, Alken P, Thüroff JW. Local excision of urothelial cancer of the upper urinary tract. *Eur Urol*. 1986; 12: 89-95.
34. Colin P, Ouzzane A, Pignot G, Ravier E, Crouzet S, Ariane MM, et al. Comparison of oncological outcomes after segmental ureterectomy or radicalnephroureterectomy in urothelial carcinomas of the upper urinary tract: results from a large French multicentre study. *BJU Int*. 2012; 110: 1134-1141.
35. Seisen T, Nison L, Remzi M, Klatter T, Mathieu R, Lucca I, et al. Oncologic Outcomes of Kidney Sparing Surgery versus Radical Nephroureterectomy for the Elective Treatment of Clinically Organ Confined Upper Tract Urothelial Carcinoma of the Distal Ureter. *J Urol*. 2016; 195: 1354-1361.
36. Simonato A, Varca V, Gregori A, Benelli A, Ennas M, Lissiani A, et al. Elective segmental ureterectomy for transitional cell carcinoma of the ureter: long-term follow-up in a series of 73 patients. *BJU Int*. 2012; 110: 744-749.
37. Dalpiaz O, Ehrlich G, Quehenberger F, Pummer K, Zigeuner R. Distal ureterectomy is a safe surgical option in patients with urothelial carcinoma of the distal ureter. *Urol Oncol*. 2014; 32: 1-8.
38. Singla N, Gayed BA, Bagrodia A, Krabbe LM, Palazzi KL, Mirheydar H, et al. Multi-institutional analysis of renal function outcomes following radical nephroureterectomy and partial ureterectomy for upper tract urothelial carcinoma. *Urol Oncol*. 2015; 33: 268 e1-7.