

Renal Metastasis from Mucinous
Adenocarcinoma of the Colon in a 70
Year Old Male: A Case ReportSultan H AlSaigh^{1*} and Aseel A AlSaeed²¹Department of General surgery, king Fahad specialist hospital, Saudi Arabia²Faculty of Medicine, Qassim University, Saudi Arabia

Article Information

Received date: Feb 08, 2018

Accepted date: May 14, 2018

Published date: May 15, 2018

*Corresponding author

Sultan H AlSaigh, General surgery consultant, head of general surgery department king Fahad specialist hospital, Buraidah, Saudi Arabia, Email: dr.sultan.s@gmail.com

Distributed under Creative Commons CC-BY 4.0

Keywords Colon cancer; Metastasis to kidney; Partial nephrectomy; Chemotherapy

Abstract

Distal Metastasis of Colorectal Cancer (CRC) mostly spread to the lymph node, liver, peritoneum and lung. The kidney metastasis from colorectal cancer considered to be unusual and rare sites of metastasis. The most important factor which affects the prognosis of colorectal cancer is distal metastasis. The present study reported the case of a 70-yr-old Saudi man metastatic mucinous adenocarcinoma of the colon in the right kidney at the time of initial presentation.

Introduction

Colorectal cancer is considered the most common cancer in Saudi Arabia among men. In addition, it is the third commonest since 2002 in Saudi Arabia among women. In 2010 the incidence ratio reached 14.5/100.000 in capital, Riyadh [1]. The most important factor which affects the prognosis is distant metastasis. The colorectal cancer commonly metastasized to lymph node, liver, peritoneal and lungs [2]. Less than 3% of secondary renal neoplasms were from primary colon cancer. Which consider a very rare metastasis [3]?

In this study report, we present a patient with metastatic mucinous adenocarcinoma of the colon in the right kidney at the time of initial presentation.

Case Report

A 70-yr old unmarried man. He is known case of bronchial asthma. He had a positive family history of cancer. He was presented to the emergency department with progressive abdominal discomfort and pain, distention, constipation and weight loss (15 kg) for the last 6 months. On clinical examination, he was severely dehydrated and very thin, pale, and cachectic. The patient was fully conscious, vitally stable. Chest and cardiovascular examination were unremarkable. Abdomen was soft and lax, but there was a dull percussion note over palpable mass on the right side of the abdomen. Digital rectal examination was negative.

Results of laboratory tests on admission were, a WBC 11.3, Hemoglobin 9.8, and Platelet 442. Album in 24.6, K 3.1, Na 132.

Chest and Abdomen x-ray were normal. A Computed Tomography (CT) scans of the abdomen done and revealed a nodular and irregular wall thickening of the cecum and proximal ascending colon extending to the ileocecal valve and extends beyond the series into the adjacent fat, bowels partially obstructed. There is free fluid in the right iliac fossa and pelvis. No perforation or ischemia. The findings were suggestive of colon cancer (Figure 1). Moreover, there is 1.7 x 1.3 cm polypoid mass in the sigmoid colon concerning for synchronous tumor. Also, there is a 3.5 x 3.5 x 2.6 cm exophytic masses in the upper pole of the right kidney (Figure 2) with typical radiological picture of renal cell carcinoma. Staging CT scan of abdomen, pelvis and thorax showed no findings of metastasis in the other organs. The nuclear medicine Bone Imaging of whole body showed the uniform radiotracer distribution with no evidence of any abnormal focal or diffuse active osseous lesions that could account for metastasis.

A diagnostic lower GI endoscopy revealed multiple colonic polyps in the sigmoid, ascending and transverse colon. Some had hyperplastic ulcerated mucosal lining. The lumen was obstructed in the ascending colon by a multipolypoidal ulcerated mass that bleeds on touch, occupying 270 degrees of the luminal circumference. The plan for total colectomy and right partial nephrectomy were performed because we considered that the patient had two primary tumors.

Final histopathological came as gross findings of the resected colonic segment was measuring as 60x7x7 cm. Large circumferential mass causing wall thickening and obstruction is seen measuring

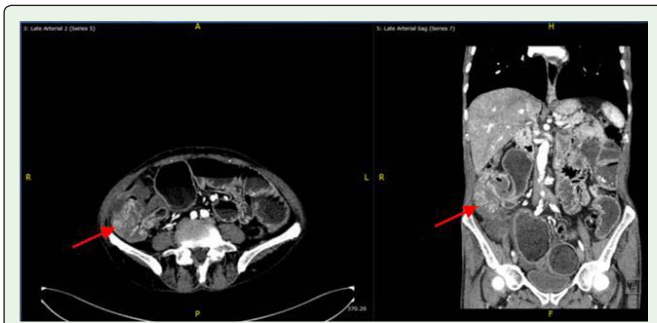

Figure 1: Abdominal computed tomography scan revealing a mass in the cecum and proximal ascending colon.

9.5x5.5 cm. A small sized, grayish red, pedunculated polyp measuring 1.5x1.5x1 cm is detected 5cm from the distal resection margin. Through dissection of pericolonic fat revealed seventeen small sized lymph node and multiple. Microscopically, revealed adenocarcinoma with strips of tumor cells floating in large extracellular mucin lakes comprising more than half of tumor mass. Signet ring cells (with intracellular mucin) are also present, comprising less than half of tumor. The sigmoid polyp was pedunculated with stalk and it measuring grossly as 1.5x1.5x1 cm with 0.5cm stalk length. Its histopathological report came as tubulovillous adenoma with low grade dysplasia / No malignancy. Gross findings of the right renal mass, its single, large-sized, oval mass with smooth nodular outer surface measuring 4.5x 3.5x2.5cm. Cut section shows homogenous yellowish white solid area among foci of hemorrhagic cysticification and necrosis. Microscopic description of renal mass came as infiltration by well-formed malignant acini is seen along with signet ring cells, extracellular mucin lakes, area of hemorrhage and necrosis. No evidence or renal cell carcinoma is identified. The immunohistochemistry results show: CDX2 strongly positive, CEA strongly positive, CK20 positive, CK-34-b-E12positive, CK7 negative which represent metastatic mucinous adenocarcinoma from colon.

Post operation the patient was well for almost one week. After that he developed abdominal pain in the 6th day. At the same time the CBC show that the WBCs was slightly elevated. Urgent CT was done showed anastomotic leak with a large amount of free fluid and pneumoperitoneum associated with reactive thickening of the small bowel and peritoneal reflections (Figure 3) because the collection wasn't amenable for percutaneous drainage, the patient was taken to operating theater for drainage and loop ileostomy. After second

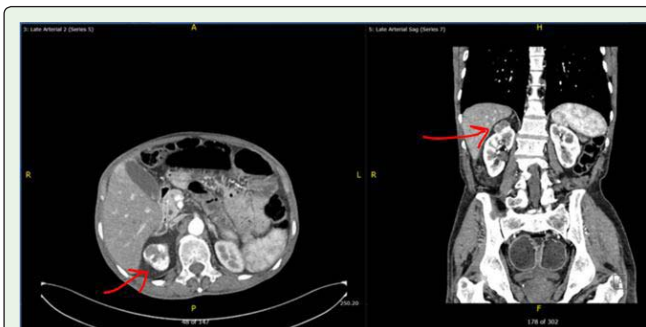


Figure 2: Abdominal computed tomography scan showed an exophytic mass in the upper pole of the right kidney.

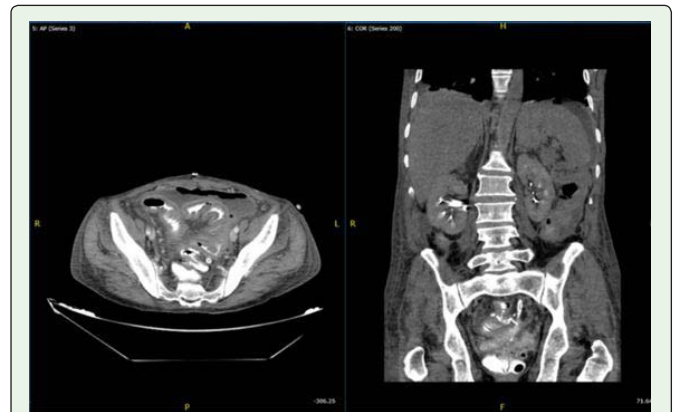


Figure 3: Pelvic computed tomography scan showed anastomotic leak with a large amount of free fluid and pneumoperitoneum.

surgery the course of admission was uneventful. After one month the patient discharged from surgical side. But the patient stayed two months for social issue. Patient now on follow up with oncologist and him received 3 cycles of Capecitabine. On the last visit he was stable with no abdominal tenderness, organomegally or ascites. And there was no peripheral lymphadenopathy, bony tenderness or lower limb edema and no add sounds over chest auscultation.

Discussion

Colorectal cancer considered as a one of the most common fatal cancers [2]. More than 90% of colorectal cancers diagnosed at 50-year-old or older [4]. World widely, 1.36 million patients are diagnosed with colorectal cancers. More than 600,000 cases are reported each year with colorectal cancer associated mortalities [5]. The mucinous adenocarcinoma of the colon accounts for 10% of all colorectal cancers. It is originated from villous adenoma after inflammatory bowel diseases and post-irritation. Metastasis in mucinous adenocarcinoma is more common and more aggressive than the other types of colorectal cancers. While, the literatures revealed that there is no much difference in the prognosis of the mucinous adenocarcinoma and the other types [6]. The most common symptoms of colorectal cancer include; change in bowel habit, Melena, bright red blood coming through rectum, fatigue, abdominal pain and discomfort with floating [7].

Around 50% of patients develop metastases and 10 to 15% of them have distal metastasis at time of the initial diagnosis. Colorectal cancers can spread by lymphatic and venous system [4,6]. The most common site of colon cancer metastasis is the lymph node, liver, peritoneum and lung. However, the kidney metastasis from colorectal cancer consider to be extremely rare [2,4,8]. Most of the patients who have kidney metastasis of colorectal cancer are asymptomatic and usually detected by imaging or by increase CEA level [4]. To the best of our knowledge, there are a few similar cases in the published literature. A study was done by Bracken et al revealed that is only 2.7% of patients with colorectal cancer out of 11,328 patient diagnosed with kidney metastasis [9,10].

The treatment of colorectal cancer depends on how advanced it, that's why there are so many classifications to stage the disease. The most accepted and widely used classification is Tumor-Node-Metastasis (TNM) classifications which have been developed by

The American Joint Committee on Cancer (AJCC) since its first edition in 1959. The classification have been revised and modified many time reaching 8th edition. TNM classification is important in determining therapeutic option as well as prognosis in which (T) for tumor invasions, (N) for number of lymph node involved and (M) for distant metastasis. Based on TNM classification, there are four stages of colorectal cancer (stage I, stage II, stage III, and stage IV); any cancer with non-nodal distant metastasis considered stage IV [11,12].

The surgical treatment for colorectal cancer is the mainstay of the treatment with or without adjuvant and neoadjuvant therapy. The principle of surgery is removing the primary tumor with its lymph vascular supply. If there is involvement to adjacent structures involved should be resected en bloc with the tumor.

If there is synchronous cancer, like in our case, the risk of carcinoma in entire colon is high, and subtotal or total colectomy must be performed. If unexpected metastatic disease is encountered during surgery, the operative decision whether to do therapeutic or palliative resection or to abort the surgery depends on the volume of distant metastasis and location & size of primary tumor. If the metastasis is low volume it is reasonable to do abdominal resection either at the same operation or staged surgery. On the other hand, if the metastatic disease is high volume (carcinomatosis), especially if the primary tumor is minimally symptomatic, the operation should be aborted in order to facilitate early chemotherapy.

References

1. Alsanea N, Abduljabbar AS, Alhomoud S, Ashari LH, Hibbert D, Bazarbashi S. Colorectal cancer in Saudi Arabia: incidence, survival, demographics and implications for national policies. *Ann Saudi Med.* 2015; 35:196-202.
2. Klaassen Z, Prabhakar R, Madiet R, Shingleton WB, Terris MK. Bilateral Metachronous Colon Cancer Metastasis to Kidneys: A Rare Case with a Treatment Dilemma. *UroToday International Journal.* 2013; 6: 38.
3. Kibar Y, Deveci S, Sümer F, Seçkin B. Renal papillae metastasis of sigmoid colon adenocarcinoma. *International Journal of Urology.* 2005; 12: 93-95.
4. Dulskas A, Bagurskas P, Sinkevicius Z, Samalavicius NE. Sigmoid adenocarcinoma with metastases to the kidney: Report of a rare case and review of the literature. *Oncol Lett.* 2015; 10: 1191-1193.
5. Ferlay J, Soerjomataram I, Dikshit R, Eser S, Mathers C, Rebelo M, et al. Cancer incidence and mortality worldwide: sources, methods and major patterns in GLOBOCAN 2012. *Int J Cancer.* 2015; 136: 359-386.
6. Aksu G, Fayda M, Sakar B, Kapran Y. Colon cancer with isolated metastasis to the kidney at the time of initial diagnosis. *Int J Gastrointest Cancer.* 2003; 34:73-77.
7. Nordqvist C. Colorectal cancer: What you need to know. *MedicalNewsToday.* 2018.
8. Nelson J, Rinard K, Haynes A, Filleur S, Nelius T. Extraluminal colonic carcinoma invading into kidney: a case report and review of the literature. *ISRN Urol.* 2011. 707154.
9. Bracken RB, Chica G, Johnson DE, Luna M. Secondary renal neoplasms: An autopsy study. *South Med J.* 1979; 72: 806-807.
10. Dagnoni C, Granero LC, Rovere RK. Sigmoid adenocarcinoma with renal metastasis. *Clin Pract.* 2011; 1: 88.
11. Hari DM, Leung AM, Lee JH, Sim MS, Vuong B, Chiu CG, et al. AJCC-7TH Edition Staging Criteria for Colon Cancer: Do the Complex Modifications Improve Prognostic Assessment? *J Am Coll Surg.* 2013; 217: 181-190.
12. O'Connell JB, Maggard MA, Ko CY. Colon Cancer Survival Rates with the New American Joint Committee on Cancer Sixth Edition Staging. *J Natl Cancer Inst.* 2004; 96:1420-1425.