

Regional Chemotherapy: Possibilities for Prevention and Treatment of Peritoneal Metastases from Gastric Cancer

Paul H Sugarbaker* and Mei Li M Kwong

Center for Gastrointestinal Malignancies, Medstar Washington Hospital Center, USA

***Corresponding author:** Paul H Sugarbaker, Center for Gastrointestinal Malignancies, Program in Peritoneal Surface Oncology, Medstar Washington Hospital Center, 106 Irving St., NW, Suite 3900, Washington, DC 20010, USA. TEL: +1-202-877-3908; FAX: +1-202-877-8602; Email: paul.sugarbaker@medstar.net

Published Date: August 08, 2016

Keywords: Gastric Cancer; Peritoneal Metastases; Carcinomatosis

Abbreviations: Hyperthermic Intraperitoneal Chemotherapy (**HIPEC**); Early Postoperative Intraperitoneal Chemotherapy (**EPIC**); Neoadjuvant Chemotherapy (**NAC**); Neoadjuvant Intraperitoneal and Systemic Chemotherapy (**NIPS**); Intraperitoneal Chemotherapy (**IP**)

INTRODUCTION

Gastric cancer is the fourth most commonly diagnosed cancer in the world with a 5-year survival rate of 25% [1,2]. In follow-up, almost half of gastric cancer patients will develop peritoneal dissemination which results in a less than 5% 5-year survival rate [3–5]. Peritoneal metastases are a common finding in primary gastric cancer found in 5 to 20% of patients at the time of gastrectomy [6]. The peritoneum is also the most common location of first recurrence observed in about half of the patients [7]. Standard of care for treatment of primary or recurrence

of gastric cancer involves surgery, intravenous chemotherapy and radiotherapy. However, because peritoneal metastases are such a major cause of treatment failure, regional chemotherapy treatments directed specifically at this component of the disease have resulted in improved outcomes. Neoadjuvant systemic chemotherapy (**NAC**), neoadjuvant intraperitoneal and systemic chemotherapy (**NIPS**), cytoreductive surgery (**CRS**) and perioperative chemotherapy including hyperthermic intraperitoneal chemotherapy (**HIPEC**) and/or early postoperative intraperitoneal chemotherapy (**EPIC**) are currently being explored [8].

The timing of these regional chemotherapy treatments for peritoneal metastases are employed at four different times in the natural history of gastric cancer. For prevention of peritoneal metastases, interventions must occur at the time of gastrectomy for primary disease. For patients with synchronous peritoneal metastases diagnosed with the primary disease, interventions may be indicated before, during and after gastrectomy. For patients with peritoneal metastases diagnosed in follow-up (metachronous peritoneal metastases) interventions may occur prior to further surgical intervention. In this manuscript, prevention of peritoneal metastases, treatment of synchronous peritoneal metastases, and treatment of metachronous peritoneal metastases will be critically evaluated. Finally, management of debilitating ascites from gastric cancer will be described. This manuscript will summarize the use and efficacy of NAC, NIPS, CRS, HIPEC and/or EPIC for prevention and treatment of peritoneal metastases of gastric cancer.

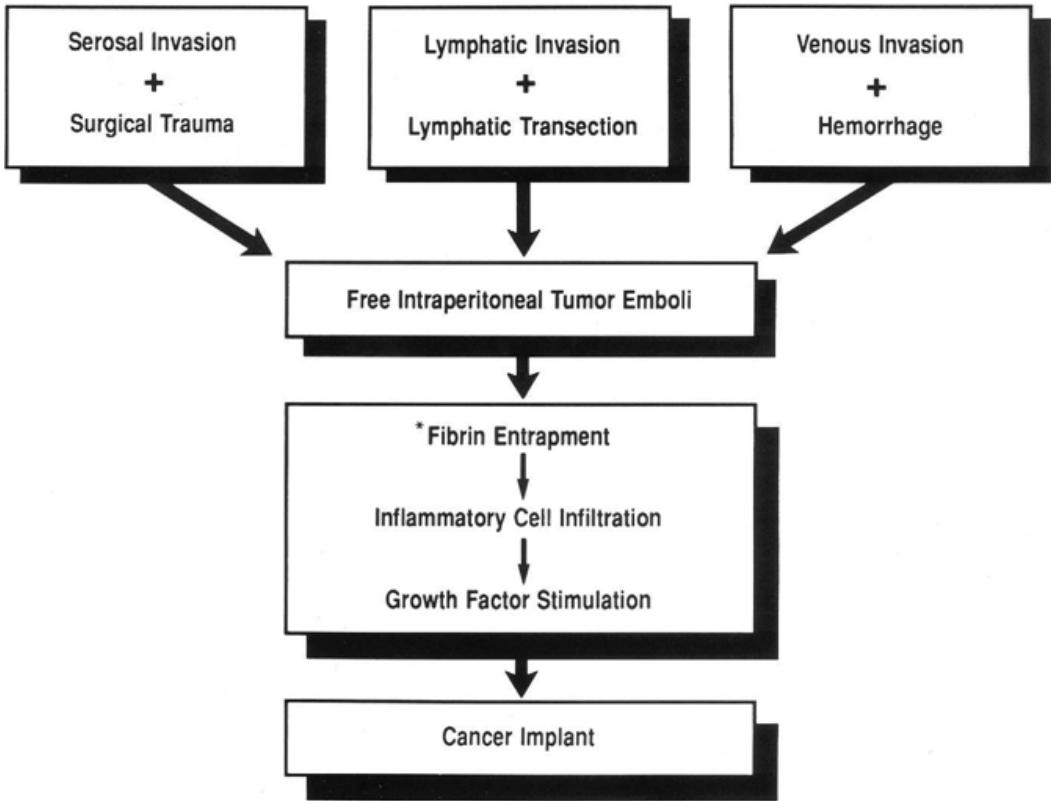
Prevention of Peritoneal Metastases

Local recurrence and peritoneal metastases are the most common sites of first recurrence in gastric cancer after curative resection [9-11]. This high incidence of local and regional disease recurrence is seen whether patients received neoadjuvant chemotherapy or postoperative adjuvant treatment as compared to surgical resection alone [12]. Less localized recurrence is observed when extended lymphadenectomy is utilized as compared to limited surgery [13-16].

Although confined to the abdomen, peritoneal seeding has deadly consequences in intraabdominal malignancies and especially gastric cancer. [16-22]. Causes of recurrence after curative resection are (1) spontaneous dissemination from the primary tumor and (2) traumatic dissemination of cancer cells during the surgical procedure. If serosal invasion has occurred spontaneous dissemination is common prior to or at the time of gastrectomy and patients are frequently found to have viable intraperitoneal cancer cells (positive cytology) [19,21-23]. Tumor cells can also find access to the peritoneal space during surgery according to the tumor cell entrapment hypothesis (Figure 1) [24]. During surgery there is disruption of lymphatics, trauma to narrow margins of resection, and tumor-contaminated blood spillage. Iatrogenically disseminated tumor cells adhere spontaneously within minutes and vascularization is facilitated by fibrin entrapment and the wound healing process. Cytokines, such as growth factors important for wound healing, may also promote tumor progression. The tumor cell entrapment hypothesis clarifies the pathogenesis of local and peritoneal metastases and creates the rationale for a

perioperative timing of intraperitoneal chemotherapy. Intraperitoneal chemotherapy should be administered in a large volume of fluid immediately after gastrectomy and before intestinal reconstruction. This is in order to access the tumor cells prior to their entrapment within fibrin and implantation within adhesive scar tissue. If the chemotherapy solution is administered after the construction of suture lines or formation of adhesions it will have uneven distribution and lack of uniform cytotoxicity for viable cancer cells. Also, kinetics of residual tumor cells change within 24 hours of resection and therefore a delay in local-regional treatments will decrease the cytotoxicity [24].

TUMOR CELL ENTRAPMENT HYPOTHESIS - RESECTED GASTRIC CANCER -



* Occurs at resection site, on abraided bowel surfaces, and beneath abdominal incision.

Figure 1: The tumor cell entrapment hypothesis suggests three mechanisms for microscopic residual cancer cells in patients having an R-0 gastrectomy. (From Sethna et al. with permission) [24].

As will be established in the data presented below, perioperative intraoperative chemotherapy can limit progression of peritoneal dissemination after curative surgery, however, it cannot treat residual disease at systemic sites or metastases within lymph nodes. Therefore, R0 gastrectomy with a complete D2 lymphadenectomy is essential. Chemotherapy penetrates into tumor nodules only by simple diffusion; therefore, it is only effective to penetrate into cancer nodules less than 1 mm [25]. Intraperitoneal chemotherapy is not effective for metastases in lymph nodes. Also, macroscopic peritoneal nodules will not be destroyed.

Perioperative intraperitoneal chemotherapy for advanced T-stage primary gastric cancer

Gastric cancer patients most likely to benefit from perioperative regional chemotherapy are those who are likely to develop peritoneal metastases diagnosed in follow-up. These are patients with positive cytology or serosal-positive (**T4**) cancers (Table 1). There have been randomized and non-randomized trials regarding perioperative intraperitoneal chemotherapy as compared to surgery alone for resectable primary gastric cancer with and without peritoneal spread. Sugarbaker, Yu, and Yonemura published a meta-analysis in 2003 of articles published in English [7]. Xu, et al published a similar study in 2004 [26]. Yan, et al published a summary of randomized control trials concerning adjuvant intraperitoneal chemotherapy for resectable gastric cancer in 2007 [27]. Feingold, et al published the most recent summary of non-randomized and randomized studies in English of HIPEC and/or EPIC to prevent peritoneal metastases in patients with gastric cancer [28].

Table 1: Clinical indications to use hyperthermic perioperative chemotherapy for primary gastric cancer in the absence of peritoneal metastases but at high risk.

1.	Positive peritoneal cytology
2.	T3 or T4 invasion of the gastric wall by endoscopic ultrasound
3.	N2 lymph nodes by CT or MRI
4.	Linitis plastica
5.	Failure to respond to neoadjuvant chemotherapy
6.	Suggested invasion of adjuvant organs or structures by CT

Yan, et al selected 10 of 13 randomized controlled trials that were judged to be of fair quality to be used in the meta-analysis [27]. There was a survival benefit associated with HIPEC (hazard ratio [HR] = 0.060; 95% CI = 0.43 to 0.83; p = 0.002) or HIPEC with EPIC (HR = 0.45; 95% CI = 0.29 to 0.68; p = 0.0002). There was a marginal effect with normothermic intraoperative intraperitoneal chemotherapy but no significant improvement in survival with EPIC alone or delayed postoperative intraperitoneal chemotherapy (Figure 2) [27].

Although there may be a survival benefit, intraperitoneal chemotherapy can increase morbidities. In the trials reviewed by Yan, even the most experienced peritoneal surface oncology

centers reported a higher morbidity and increased cost [29–31]. With EPIC there was an associated greater risk for intra-abdominal abscess (RR = 2.37; 95% CI = 1.32 to 4.26; p = 0.003) and neutropenia (RR = 4.33; 95% CI = 1.49 to 12.61; p = 0.007) [27]. Yu et al. reporting on the use of EPIC saw an increased risk of intra-abdominal abscess as compared to the control patients [32]. The meta-analysis demonstrated a significantly higher risk of neutropenia in patients treated with intraperitoneal chemotherapy [27].

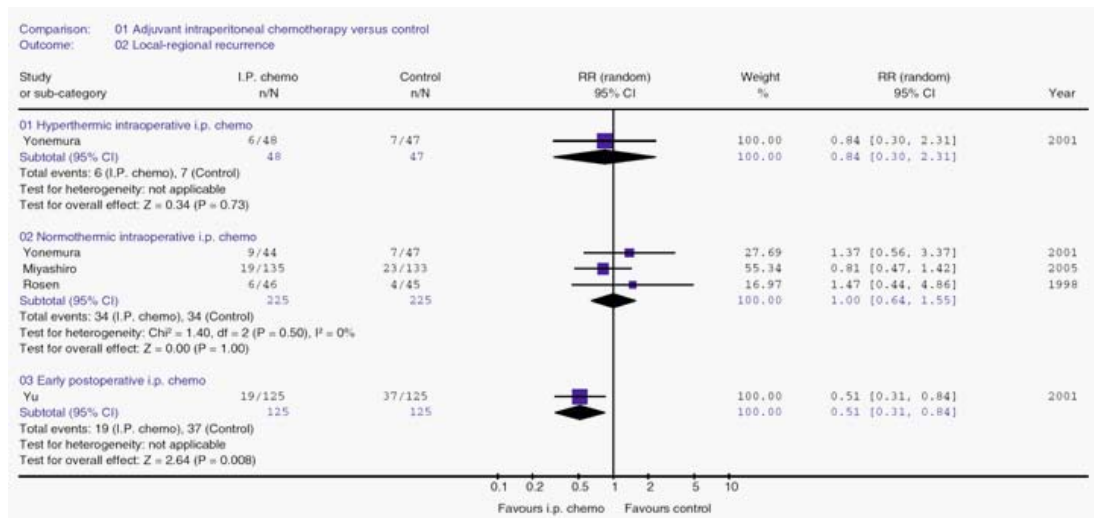


Figure 2: Forest plot of the relative risk (RR) of the local-regional recurrence with adjuvant intraperitoneal (IP) chemotherapy versus controls for advanced gastric cancer. The studies were analyzed according to the regimens of intraperitoneal chemotherapy used. The estimate of the RR of each individual trial corresponds to the middle of the squares and horizontal line gives the 95% confidence interval (CI). On each line, the numbers of events, expressed as a fraction of the total number randomized, are shown for both treatment groups. For each subgroup the sum of the statistics, along with the summary RR, is represented by the middle of the solid diamonds. (From Yan et al. with permission) [27].

Most of the trials studied by Yan were completed in Asia and it is unknown if they can be compared with gastric cancer in Western countries. It is possible that the impact of perioperative intraperitoneal chemotherapy to reduce the incidence of peritoneal metastases may be greater in Western patients with more advanced disease and less lymph nodes dissected. Data from Asia does suggest a role for HIPEC with or without EPIC to improve overall survival for primary gastric cancer with advanced T-stage and no peritoneal metastases. A Western prospective multi-institutional randomized controlled trial (**GASTRICHIP**) with well-defined eligibility criteria, interventions and end-points is currently in progress in France [33].

There are many possible perioperative chemotherapy regimens that can be combined with gastrectomy, lymphadenectomy, and resection of all visible peritoneal metastases. One

which produces a maximal local effect on peritoneal surfaces combines heated intraperitoneal chemotherapy with heat-targeted systemic chemotherapy. The systemic chemotherapy agent chosen for this targeting is ifosfamide. Table 2 presents the drugs, doses, and treatment durations for one particular HIPEC regimen that is effective and safe for application along with primary gastric cancer resection. The intraperitoneal and systemic chemotherapy are administered after the complete resection of the malignancy but prior to any reconstruction of the gastrointestinal tract or closure of the abdominal incision. This sequential application of the treatments is, theoretically, the strategy most likely to completely avoid tumor cell entrapment.

Table 2: Standardized orders for hyperthermic perioperative chemotherapy for primary gastric cancer at high risk for peritoneal metastases. This chemotherapy treatment is used after D2 gastrectomy but prior to intestinal anastomoses and abdominal closure.

<i>For intraperitoneal (IP) administration:</i>	
1.	Add cisplatin _____ mg (50 mg/m ²) to 2 liters of 1.5% dextrose peritoneal dialysis solution. Add doxorubicin _____ mg (15 mg/m ²) to same 2 liters of 1.5% dextrose peritoneal dialysis solution to maintain 1.5 liters/m ² of chemotherapy solution.
<i>For IV administration:</i>	
2.	Add ifosfamide _____ mg (1300 mg/m ²) to 1 liter 0.9% sodium chloride. Begin continuous IV infusion over 90 minutes simultaneously with IP chemotherapy.
3.	Add mesna disulfide _____ mg (260 mg/m ²) to 100 ml 0.9% sodium chloride to be given IV as a bolus 15 minutes prior to ifosfamide infusion.
4.	Add mesna disulfide _____ mg (260 mg/m ²) to 100 ml 0.9% sodium chloride to be given IV as a bolus 4 hours after ifosfamide infusion begins.
5.	Add mesna disulfide _____ mg (260 mg/m ²) to 100 ml 0.9% sodium chloride to be given IV as a bolus 8 hours after ifosfamide infusion begins.
6.	Send all the above to operating room # _____ at _____ o'clock on _____ (Date) for a 90-minute treatment.

Primary Gastric Cancer with Synchronous Peritoneal Metastases

In the past, gastric cancer with peritoneal dissemination was considered to be uniformly lethal. Prospective studies had a median survival of less than 6 months [34]. Although response rates to systemic chemotherapy regimens have improved, there has not been a corresponding improvement in survival rates [35].

CRS and HIPEC

There is a potential for long-term survival for patients with gastric cancer and peritoneal metastases if complete resection of the primary disease including wide resection of regional lymph nodes and the peritoneal metastases is combined with HIPEC. There are single institution data and phase II studies that supports use of this strategy (Table 3) [20,29–31,36–40] Glehen et al. studied 159 patients with a median follow-up of 20.4 months. There was a median overall survival of 9.2 months but the 5-year survival rate was 13% [30]. Although CRS and HIPEC are less effective for gastric cancer with peritoneal metastases than other intra-abdominal malignancies with peritoneal surface dissemination; data shows that CRS and HIPEC results in improved survival of gastric cancer versus surgery alone. Gastric cancer patients with peritoneal metastases treated with CRS and HIPEC were the only patients that experienced any 5-year survivals [37,38,41].

Table 3: Reports of patients with gastric peritoneal metastases treated by cytoreductive surgery and hyper thermic intraperitoneal chemotherapy (CC-0 = complete macroscopic cytoreduction; CC-1 = residual tumor nodules <5 mm; MMC = mitomycin C; N = number of patients) (Adapted from Glehen et al. with permission) [40].

Reference	Year	N	Anticancer Agent Used During HIPEC	Median Survival (months)	1-year Survival (%)	3-year Survival (%)	5-year Survival (%)
Fujimoto et al [20]	1997	48	MMC	16	54	41	31
Hirose et al [36]	1999	17	MMC-cisplatin-etoposide	11	44	-	-
Rossi et al [37]	2003	13	MMC-cisplatin	15	-	-	-
Glehen et al [38]	2004	49	MMC	10.3	48	-	16
CC-0 or CC-1	2004	25		21.3	74.8		29.4
Hall et al [31]	2004	34	MMC	-	-	-	-
CC-0				11.2	45		
Yonemura et al [29]	2005	107	MMC-cisplatin-etoposide	11.5	-	-	6.5
CC-0		47		15.5	-	-	27
Scaringi et al [39]	2008	32	MMC-cisplatin	6.6	-	-	-
CC-0		8		15			
Glehen et al [30]	2010	159	Various	9.2	43	18	13
CC-0		85		15	61	30	23

Studies reported to date may underestimate the potential of CRS with HIPEC to cause long-term survival of gastric cancer patients with peritoneal metastases. There were variable patient selection criteria utilized. The extent of peritoneal metastases as measured by Sugarbaker’s Peritoneal Cancer Index (**PCI**) significantly influences survival and is correlated with the completeness of cytoreduction [42]. Cytoreductive surgery must reduce the residual disease to a minimum for intraperitoneal chemotherapy to be effective (due to minimal chemotherapy penetration). Glehen et al. demonstrated a 5-year survival of 23% and a median survival of 15 months in patients after a complete macroscopic resection (Figure 3) [30]. Yonemura et al. demonstrated a similar

27% 5-year survival rate and 15.5 months median survival [29]. Hall, et al reported a 11.2 month overall survival after CRS and HIPEC with mitomycin C, however there was no patient alive after 2 years who had residual disease at CRS [31]. CRS with a microscopic residual disease burden is essential for effective HIPEC. HIPEC used with macroscopic disease does not improve survival. HIPEC can have morbidity and therefore should not be used for patients with bulky residual disease, although its palliative use for ascites may always be considered (see below).

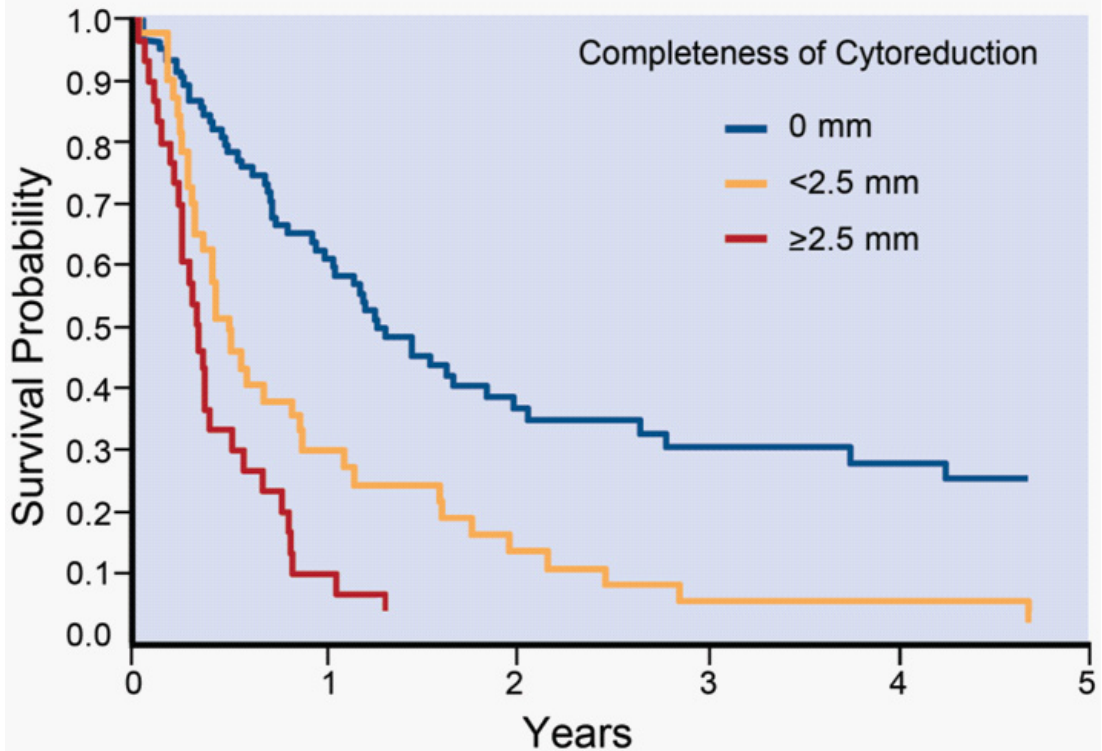


Figure 3: Overall survival of 159 patients treated by cytoreductive surgery and hyper thermic intraperitoneal chemotherapy according to completeness of cytoreductive surgery. (From Glehen et al. with permission) [30].

Even if completely cytoreduced, HIPEC is less effective for patients with a large extent of peritoneal metastases. Glehen et al. showed that one of the strongest prognostic factors was extent of carcinomatosis [30]. When the peritoneal cancer index (PCI) was greater than 12, despite a complete cytoreduction, there were no survivors greater than 3 years (Figure 4) [30]. Fujimoto, et al reported 40 to 50% 5-year survival for limited peritoneal metastases but only an 18% 1-year survival for patients with extensive peritoneal metastases [20]. Cytoreduction with HIPEC in gastric cancer patients with a PCI score greater than 12 may be contraindicated [30]. Table 4 lists clinical features useful in selection of patients for treatment of primary gastric cancer with peritoneal metastases.

Yang et al. reported the only phase III study regarding CRS and HIPEC in gastric cancer presenting with peritoneal metastases. They used cisplatin (120 mg) and mitomycin C (30 mg) in 6000 mL of normal saline at 43°C for 60-90 minutes. Median follow-up was 32 months; 97.1% (33 of 34) of patients after CRS died as compared to 85.3% (29 of 34) of CRS and HIPEC patients died. Median survival was 6.5 months (95% CI 4.8 to 8.2 months) after CRS and 11 months (95% CI; 10.0 to 11.9 months) in CRS and HIPEC group ($p = 0.046$) [43]. There was similar morbidity between the groups. The independent predictors in a multivariate analysis for improved survival were synchronous peritoneal metastases, CC 0 – 1 cytoreduction, more than 6 cycles of systemic chemotherapy, and no adverse events. These data and other reports confirm that CRS and HIPEC for patients with peritoneal metastases can result in a survival benefit but should be restricted to a limited patient population (Table 4) [43-47].

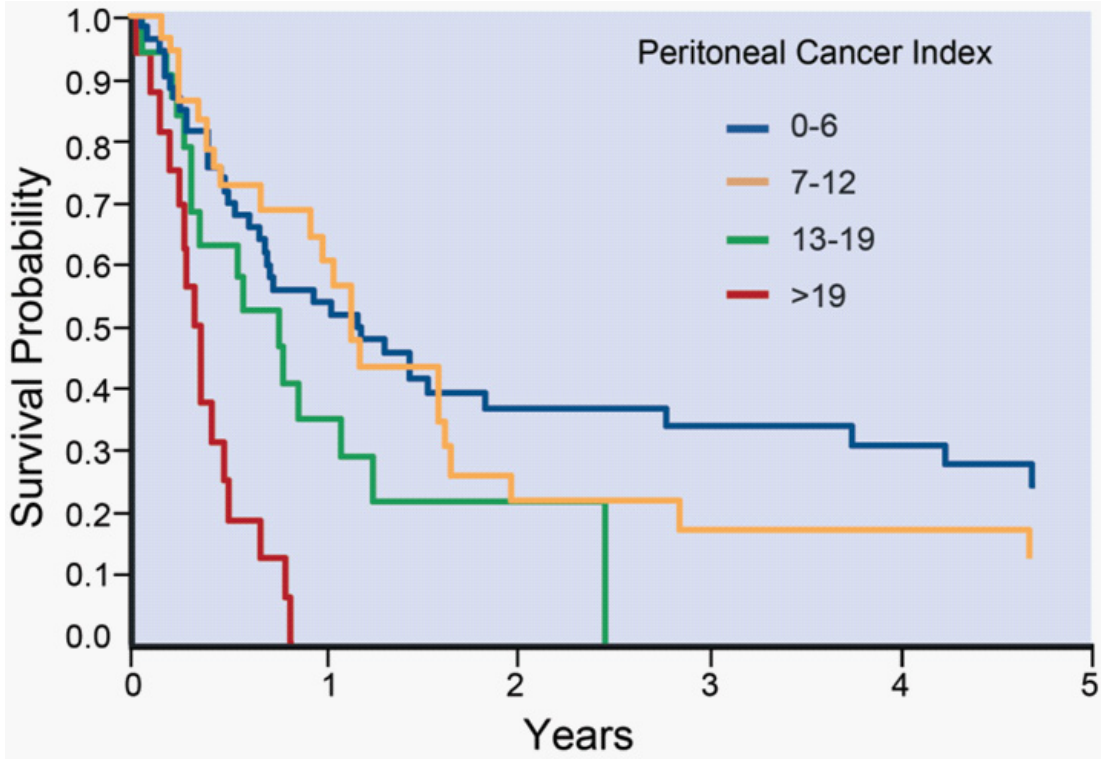


Figure 4: Overall survival of 159 patients treated by complete cytoreductive surgery according to extent of peritoneal metastases assessed by the Peritoneal Cancer Index. (From Glehen et al. with permission) [30].

Table 4: Selection of gastric cancer patients with peritoneal metastases for gastrectomy, peritonectomy, and hyperthermic perioperative chemotherapy. (Adapted from Glehen et al. with permission) [40].

CLINICAL FEATURES			
•	Young age (<65 years)		• Lymph nodes, negative or limited extent
•	Low operative risk (no other diseases)		• No liver metastases
•	Patient symptoms present		• Peritoneal Cancer Index <12
-	Pain	- Obstruction	• Expect complete clearing of the primary cancer
-	Bleeding	- Ascites	
-	Perforation		

Laparoscopy in patients with gastric cancer

Garofalo and Valle established that laparoscopy has an important role in the management of peritoneal metastases [48]. First, laparoscopy may identify patients who have peritoneal metastases even though no ascites is present and an abdominal CT is normal. It is a very accurate test to confirm a diagnosis of peritoneal metastases. If a primary gastric cancer patient is found to have peritoneal metastases more effective treatments that surgery alone can be implemented in a timely manner. Often the morbidity of a laparotomy with no benefit can be avoided [49]. Laparoscopy is useful to establish the presence versus absence of metastases.

Second, laparoscopy performed in primary gastric cancer patients can estimate the extent of peritoneal metastases, facilitating the selection of patients with a low volume (P1 or PCI < 10) of peritoneal metastases for CRS with gastrectomy and HIPEC. In these patients with minimal disease who can undergo complete cytoreduction with HIPEC, a 5-year survival of 25% is expected.

A third use of laparoscopy is serial exams in patients being treated for a greater extent of peritoneal metastases. If on repeat laparoscopic examination the peritoneal metastases respond, CRS with gastrectomy and HIPEC may become a treatment option. Alternatively, laparoscopy may have a therapeutic effect if combined with HIPEC [50]. The use of laparoscopy with NIPS (neoadjuvant intraperitoneal and systemic chemotherapy) will be described in the following sections.

Neoadjuvant Intraperitoneal and Systemic Chemotherapy (NIPS)

Cunningham and coworkers showed that systemic neoadjuvant chemotherapy may have benefit in patients with primary gastric cancer [51]. If patients have peritoneal dissemination, the effects of systemic chemotherapy are disappointing. Preusser et al. demonstrated that an aggressive systemic chemotherapy regimen can have a 50% response rate in advanced gastric cancer, however this response is less robust in patients with peritoneal metastases [52] Ajani et al. gave neoadjuvant chemotherapy; treatment failure of the regimen was most common in patients with peritoneal metastases [53]. Systemic chemotherapy alone for primary gastric cancer with peritoneal metastases results in short-term survival.

Several recent reports show that neoadjuvant chemotherapy for gastric cancer with peritoneal metastases can be improved by combining systemic and intraperitoneal chemotherapy [54-56]. With this strategy chemotherapy may not only gain access to small peritoneal cancer nodules via the systemic circulation but also by diffusion from a chemotherapy solution within the peritoneal cavity. Yonemura and coworkers reported data from a prospective phase II study to identify the efficacy and assess toxicities in patients with primary gastric cancer with peritoneal metastases [56]. The following summarizes this study.

Patients treated

In this phase II study, Yonemura and coworkers treated patients with biopsy-proven peritoneal metastases identified by laparoscopy, laparotomy or cytology from ascites. To be treated with NIPS, patients must have (1) proven peritoneal seeding by histology or cytology, (2) no hematogenous or remote lymph node metastases, (3) be less than or equal to 65 years, (4) an Eastern Clinical Oncology Group score of 2 or less, (5) adequate bone marrow, liver, cardiac, and renal function, and (6) no other severe medical comorbidities or synchronous malignancies.

Qualifying patients had a peritoneal port system (Bard Port, C.R. Bard Inc., USA) inserted into the abdominal cavity under local anesthesia with the catheter tip placed within the cul-de-sac of Douglas.

Chemotherapy regimen

Prior to administration of chemotherapy, 500 mL of saline was instilled into the peritoneal cavity and fluid was removed for cytology. Docetaxel 40 mg and carboplatin 150 mg were used for intraperitoneal chemotherapy in addition to 1000 mL of saline over 30 minutes. Methotrexate 100 mg/m² and 5-fluorouracil 600 mg/m² in 100 mL of saline over 15 minutes were administered intravenously the same day. This regimen was administered weekly for two cycles. After the second cycle, peritoneal wash cytology was again performed. If cytology was positive, neoadjuvant chemotherapy was continued for 2 more cycles. Peritoneal cytology testing was repeated after the fourth cycle and the process was continued as long as cytology was positive [56].

If cytology became negative, upper endoscopy, repeat laparoscopy and CT scan were performed. If the primary gastric cancer showed no response, then 2 more cycles of NIPS were administered. The number of NIPS chemotherapy cycles was controlled by the effect on the primary cancer and peritoneal cytology. Complete cytoreduction was required for prolonged survival in prior studies of peritoneal metastases. Therefore, the goal of the NIPS regimen was complete or near complete response of metastases on small bowel surfaces so that gastrectomy plus cytoreduction resulted in complete visible clearing of the abdomen and pelvis.

The Japanese General Rules for Gastric Cancer Study was used to determine the peritoneal stage as **(P1)** peritoneal metastases in the upper abdomen above the transverse colon, **(P2)** several countable metastases in the peritoneal cavity, and **(P3)** numerous metastases in the

peritoneal cavity. Distribution and size of peritoneal metastases were recorded at laparoscopy and at surgery. Tumor location, size and number were evaluated before and after NIPS to determine effects of neoadjuvant chemotherapy.

Surgery for Gastric Cancer with Peritoneal Metastases after Neoadjuvant Intraperitoneal and Systemic Chemotherapy (NIPS)

Gastrectomy and peritonectomy were performed if peritoneal wash cytology became negative or there was a partial response to neoadjuvant chemotherapy. Patients with progressive disease or who continue to have positive cytology despite 6 cycles of NIPS were not candidates for surgery.

If peritoneal metastases on small bowel surfaces were eliminated by NIPS, there was a possibility that gastrectomy and parietal peritonectomy could achieve a complete cytoreduction. Sugarbaker and Yonemura reported the use of peritonectomy for peritoneal metastases to cytoreduce the peritoneal surface and facilitate total resection of the primary gastric cancer [7]. Peritonectomies required for gastric cancer have been described [57,58]. The epigastric peritonectomy includes any prior midline abdominal scar with the preperitonealepigastric fat pad, xiphoid process, round and falciform ligaments. The anterolateral peritonectomy removes the greater omentum with the anterior layer of peritoneum from the transverse mesocolon, peritoneum of the right paracolic gutter along the appendix, and the peritoneum in the right subhepatic space. Sometimes the peritoneum of the left paracolic gutter must also be removed. The subphrenic peritonectomy takes the peritoneal surfaces from the medial half of the right and left hemidiaphragm as well as the left triangular ligament. The omental bursa peritonectomy starts with cholecystectomy and then removes the peritoneal covering of the portahepatis, hepatoduodenal ligament, and floor of the omental bursa including the peritoneum overlying the pancreas. If tumor was within the cul-de-sac, a pelvic peritonectomy was also performed and electroevaporative surgery strips the peritoneum from the pouch of Douglas. Sometimes, the pelvic peritonectomy will necessitate removal of the rectosigmoid colon. Visceral resections and parietal peritonectomies were performed to completely remove visible disease.

Any complications related to chemotherapy and peritonectomy were prospectively collected and verified retrospectively.

Results after Neoadjuvant Intraperitoneal and Systemic Chemotherapy (NIPS) plus Gastrectomy with Cytoreduction

Several single institution reports have focused on NIPS with cytologic and laparoscopic monitoring for selection of patients for gastrectomy with cytoreduction. A recent report by Canbay et al. is a phase II study of NIPS including 194 patients. Average age was 51.5 years. One-hundred-four patients had primary gastric cancer and 90 patients had recurrent peritoneal metastases [59]. Prior to NIPS peritoneal fluid cytology was positive in 137 patients and negative in 57 patients. There was complete resolution of peritoneal metastases after NIPS chemotherapy in 24.3% of patients. After induction treatment, 152 patients were judged to respond sufficiently to undergo surgery.

Operative interventions are displayed in Table 5, total gastrectomy (n = 94), subtotal gastrectomy (n = 17), small bowel resection (n = 44). Left and right sub diaphragmatic peritonectomy and pelvic peritonectomy was completed in 44, 31, and 61 patients, respectively. Complete cytoreduction was achieved in 103 (67.7%) of patients.

Figure 5 demonstrates overall survival of the 194 patients. Median survival was 15.8 months for the 152 patients who had received surgical intervention versus 7.5 months for patients who did not have an operation. Median survival of the 194 patients was 14.4 months. One-year survival was 54% for all patients. There was a significant survival difference (p = 0.03) between patients who underwent operative intervention versus those who did not. There was a higher median survival of 18 months for patients who received a complete cytoreduction. There was no difference between primary and recurrent disease after cytoreduction with a median survival of 17.6 months versus 14.1 months, respectively (p = 0.39) (see discussion below).

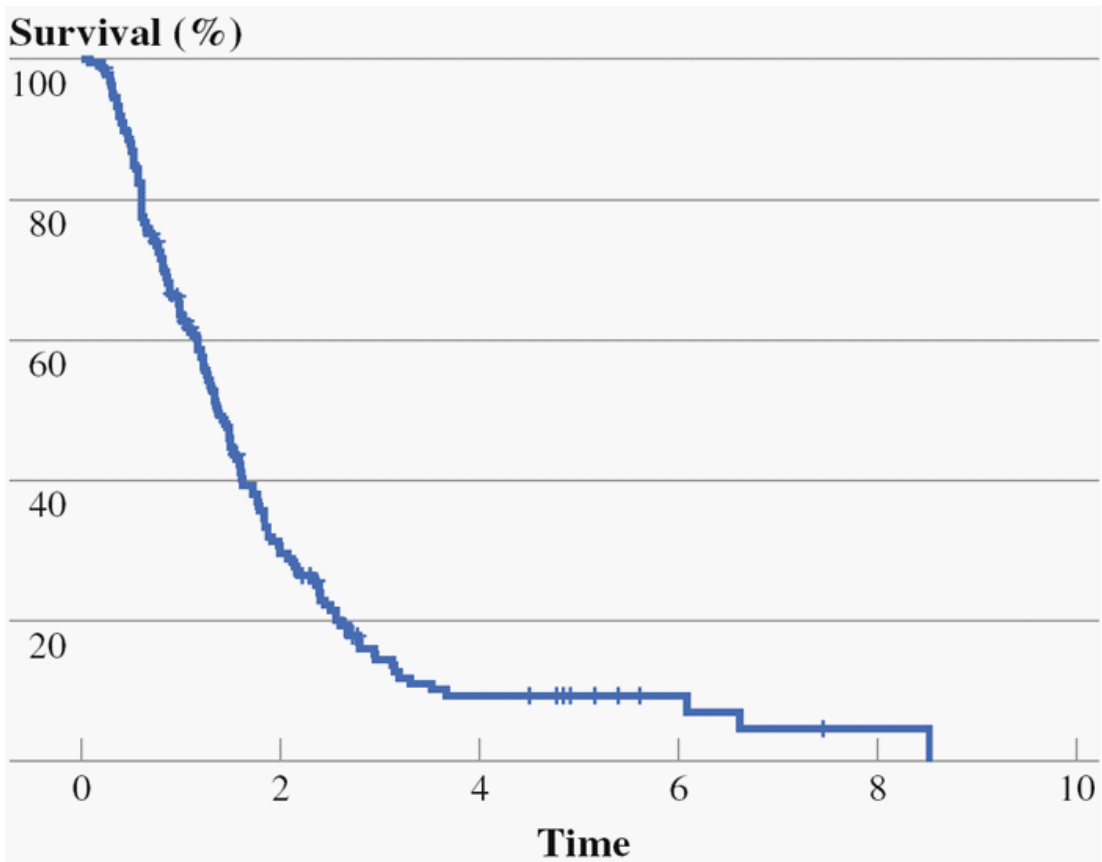


Figure 5: Overall survival in 194 gastric cancer patients with peritoneal carcinomatosis. (From Canbay et al. with permission) [59].

Adverse events from neoadjuvant intraperitoneal and systemic chemotherapy (NIPS) and gastrectomy plus cytoreductive surgery

The most common chemotherapy-related grade 3 or 4 adverse events were bone marrow suppression, diarrhea and renal failure. Less common adverse events were port site infection (n = 2) and renal failure (n = 1). After cytoreduction with peritonectomy, in 152 patients, 36 (23.6%) developed complications. The overall operative mortality rate was 3.9% (6 of 152 patients). Thirteen patients developed sepsis associated with anastomotic leakage [59].

Another approach to the concept of NIPS has been reported by Kitayama and colleagues [60]. They used oral S1 combined with intraperitoneal paclitaxel (20 mg/m²) and intravenous paclitaxel (50 mg/m²) on days 1 and 8. S1 was administered at 80 mg/m² per day for 14 consecutive days. Gastrectomy was considered in fit patients if 1) no distant metastases occurred except in the peritoneal cavity, 2) peritoneal cytology became negative, 3) by laparoscopy peritoneal nodules were reduced or under control. Of 60 patients treated approximately half (34) were able to have gastrectomy. Median overall survival for 60 patients was 16.6 months, for the 34 having gastrectomy it was 26.4 months and for the 30 who did not have gastrectomy, it was only 12.1 months. Statistical analyses were not provided.

Yet another approach to NIPS was reported by Fujiwara and coworkers [61]. They used intraperitoneal Docetaxel (40-60 mg/m²) combined with oral S1 at 40 mg/m² twice daily. After 2 cycles repeat laparoscopy was performed. At post-NIPS evaluation, 14 patients had negative peritoneal cytology and no macroscopic peritoneal metastases. Sixteen patients had gastrectomy. Median overall survival for all patients was 24.6 months. These data strongly suggest a benefit from NIPS combined with gastrectomy plus cytoreduction.

Treatment of metachronous peritoneal metastases

Peritoneal metastases diagnosed in follow-up after definitive treatment of the primary gastric cancer have always been regarded as a terminal condition. Palliative systemic chemotherapy is usually recommended but is only of small short-term benefit. Yang and coworkers in the phase III study of HIPEC in gastric cancer with peritoneal metastases treated 10 patients with metachronous disease [43]. The median overall survival of these patients was 5.5 months. For 24 patients with synchronous peritoneal metastases treated with CRS and HIPEC the median survival was 12.0 months. These two groups were statistically significantly different, with a p-value of 0.02. In the trial of Yang and coworkers, metachronous peritoneal metastases were not successfully treated by CRS and HIPEC.

In the study using NIPS reported by Canbay et al., 104 patients had synchronous peritoneal metastases and 90 had metachronous peritoneal metastases [59]. Median overall survival of the two groups was 17.6 versus 14.1 months; the difference was not significant with a p-value of 0.39. Significant differences evident for PCI ≤ or >6, complete versus incomplete cytoreductive surgery and marked versus minimal response to NIPS. This report would indicate that NIPS followed

by cytoreductive surgery plus gastrectomy is a treatment option for peritoneal metastases diagnosed in follow-up. Cytoreductive surgery plus HIPEC in the absence of NIPS was not shown to be effective.

Favorable outcomes from NIPS as compared to systemic chemotherapy

An alternative approach to management of gastric cancer with peritoneal metastases by NIPS is to use induction systemic chemotherapy. Han and coworkers used six different systemic chemotherapy options to treat 34 patients who had primary gastric cancer with metastases [62]. These highly patients were judged to be “good responders” to systemic chemotherapy. At the time of gastrectomy, five patients had no residual tumor. There were 26 R0 resections with a median overall survival of 22.9 months. Non-R0 resections survived 7.8 months.

Intraperitoneal ports and NIPS regimens

Improved outcomes for long-term combine intraperitoneal and intravenous chemotherapy have been reported for ovarian cancer, peritoneal mesothelioma, and now gastric cancer. A major impediment to the acceptance of intraperitoneal chemotherapy administration is a high incidence of adverse events associated with the intraperitoneal port [63]. Sugarbaker reported a lower incidence of adverse events when the port was placed at the time of cytoreductive surgery [64]. There is a sharp contrast of intraperitoneal port for ovarian cancer and peritoneal mesothelioma as compared to its use for NIPS with gastric cancer. In the former use the port must function after the cytoreductive surgery and within the resulting peritoneal adhesions. In gastric cancer patients the port for NIPS is placed prior to surgery and intestinal adhesions are not expected to interfere with intraperitoneal chemotherapy administration.

In the report by Canbay, 194 patients were treated using an intraperitoneal infusion of Docetaxel (30 mg/m²) and cisplatin (30 mg/m²) for three consecutive days on a monthly cycle [59]. They reported hematologic complications at 2.5%, gastrointestinal toxicity at 26.2% and a single patient experiencing renal failures. No problems with failure to infuse, infection, or pain were described. Kitayaman treated 64 patients using a peritoneal access device [60]. Paclitaxel was administered intravenously at 50 mg/m² and intraperitoneally at 20 mg/m² on days 1 and 8 with these treatments being repeated every three weeks. The manuscript does not list any complications associated with the intraperitoneal access device. Fujiwara and coworkers infused through a “drainage tube” between 40 to 60 mg/m² of Docetaxel in one liter of saline [61]. These treatments were repeated every three weeks. No adverse events with the intraperitoneal chemotherapy administration were reported.

According to these data, or a lack thereof, intraperitoneal administration of chemotherapy in patients with peritoneal metastases from gastric cancer has few adverse events. Some moderate to low level of hematologic toxicity from intraperitoneal taxanes is to be expected. However, port malfunction was not an issue in these patients.

All clinical data supports complete cytoreduction as the goal in management of gastric cancer patients with peritoneal seeding

Complete cytoreduction is crucial in the surgical treatment for carcinomatosis from appendiceal and colon cancer. Five-year survival for complete cytoreduction was 54% versus 15% for incomplete cytoreduction as reported by Culliford, et al [65]. Glehen, et al also reported a median survival difference of 32 months and 8.4 months for patients with macroscopic complete resection versus incomplete cytoreduction, respectively [66]. This has been shown that complete cytoreduction had better survival rates in gastric cancer [43-47]. There is a difference in biological aggressiveness between colon and gastric cancers; however, macroscopic complete cytoreduction is necessary for long-term survival with peritoneal metastatic disease in these diseases. If there is P3 dissemination, complete cytoreduction should not be attempted unless NIPS was shown to markedly diminish disease on intestinal surface and thereby facilitate complete cytoreduction.

Palliative benefits to all patients with cancerous ascites

There was improvement in symptoms for patients with advanced gastric cancer who had ascites [40]. These benefits occurred in patients with primary gastric cancer and also in patients with recurrent disease. Cunliffe et al. hypothesized that peritoneal metastases are nourished via ascites as well as blood supply. Therefore, peritoneal implants should be treated via a combined intraperitoneal and intravenous approach [67]. Intravenous chemotherapy has minimal effects on peritoneal metastases [52,53]. The bidirectional chemotherapy (intraperitoneal and intravenous) has a response rate of 57% with near 100% resolution of ascites [40].

Chemotherapy agents selected for neoadjuvant intraperitoneal and systemic chemotherapy (NIPS)

Different chemotherapy regimens have been used for NIPS such as docetaxel, cisplatin, and paclitaxel. Fujiwara, et al irrigated the abdominal cavity with doses of docetaxel between 40 to 60 mg/m² dissolved in 1L of saline [61]. Canbay, et al administered intraperitoneal docetaxel (30 mg/m²) and cisplatin (30 mg/m²) combined with oral S1 [59]. Kitayama's group administered paclitaxel at 20 mg/m² in 1L of normal saline over one hour combined with 50 mg/m² paclitaxel intravenously and oral S1 [60]. The optimal dose and schedule for the intraperitoneal chemotherapy and intravenous chemotherapy and the timing of one treatment with respect to the other has not yet been determined. Also, the use of or non-use of HIPEC with gastrectomy in selected patients has not yet been determined. These early studies show benefit but need further investigation.

SUMMARY

Prevention of peritoneal metastases may be the most important new strategy for management of selected gastric cancer patients at high risk for local-regional failure. In patients with low volume peritoneal metastases with primary gastric cancer (synchronous disease), HIPEC will

improve outcome. In patients with a larger extent, NIPS should be considered in gastric cancer patients with peritoneal metastases using serial cytology and laparoscopy to select patients for gastrectomy and peritonectomy. NIPS has maximal benefits for peritoneal surface metastases that have responded to treatment. It may be used with synchronous and metachronous peritoneal metastases and is reliable treatment for symptomatic ascites. The bidirectional chemotherapy that NIPS provides may be a preferred strategy as compared to systemic NAC for preoperative chemotherapy of gastric cancer with peritoneal metastases (Figure 6).

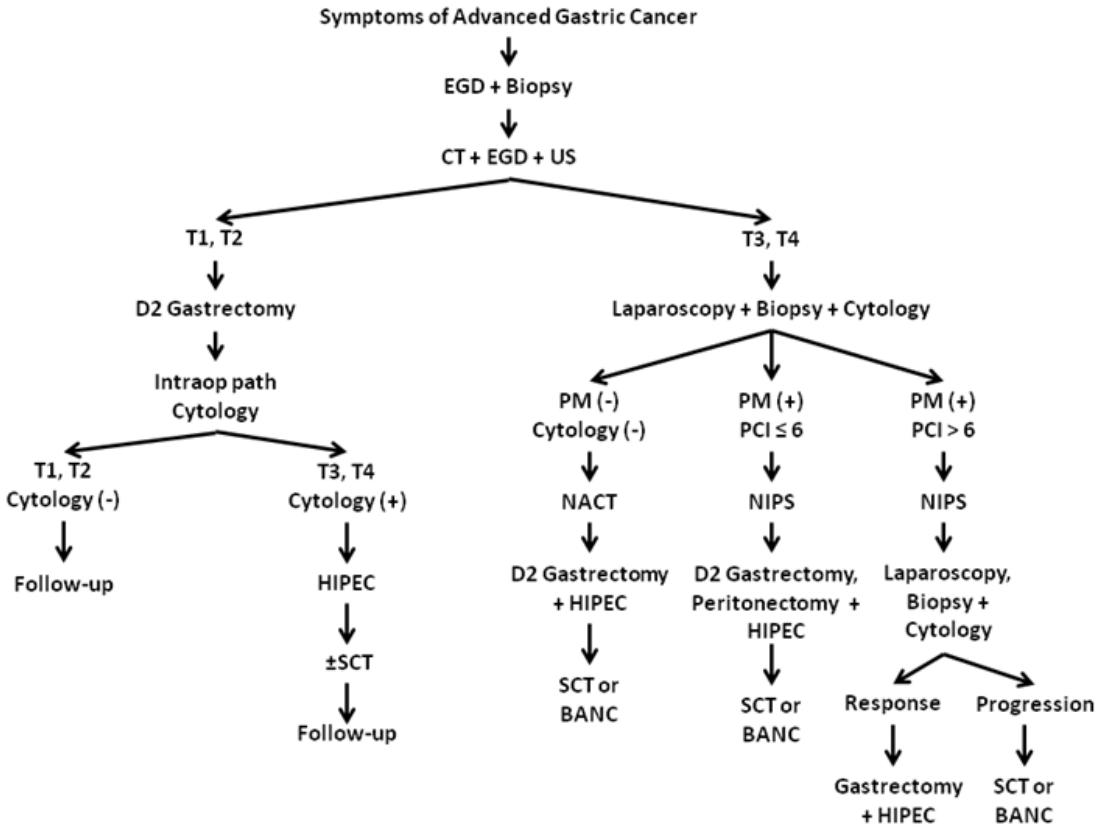


Figure 6: Algorithm for management of advanced gastric cancer. EGD = esophagogastroduodenoscopy; CT = computed tomography; US = ultrasound; HIPEC = hyperthermic perioperative chemotherapy with intraperitoneal cisplatin, doxorubicin, and systemic ifosfamide, MESNA; SCT= systemic chemotherapy; PCI = peritoneal cancer index; NACT = neoadjuvant chemotherapy; NIPS = neoadjuvant intraperitoneal paclitaxel and systemic oxaliplatin chemotherapy; BANC = bidirectional adjuvant normothermic chemotherapy with intraperitoneal paclitaxel and systemic oxaliplatin.

References

1. Berretta M, Fisichella R, Borsatti E, Lleshi A, Ioffredo S. Feasibility of intraperitoneal Trastuzumab treatment in a patient with peritoneal carcinomatosis from gastric cancer. *Eur Rev Med Pharmacol Sci.* 2014; 18: 689-692.
2. Jemal A, Bray F, Center MM, Ferlay J, Ward E. Global cancer statistics. *CA Cancer J Clin.* 2011; 61: 69-90.
3. Sarela AI, Miner TJ, Karpeh MS, Coit DG, Jaques DP. Clinical outcomes with laparoscopic stage M, unresected gastric adenocarcinoma. *Ann Surg.* 2006; 243: 189-195.
4. Brenner H, Rothenbacher D, Arndt V. Epidemiology of stomach cancer. *Methods Mol Biol.* 2009; 472: 467-477.
5. Cappellani A, Zanghi A, Di Vita M, Zanet E, Veroux P. Clinical and biological markers in gastric cancer: update and perspectives. *Front Biosci.* 2010; 2: 403-412.
6. Hioki M, Gotohda N, Konishi M, Nakagohri T, Takahashi S. Predictive factors improving survival after gastrectomy in gastric cancer patients with peritoneal carcinomatosis. *World J Surg.* 2010; 34: 555-562.
7. Sugarbaker PH, Yu W, Yonemura Y. Gastrectomy, peritonectomy and perioperative intraperitoneal chemotherapy: the evolution of treatment strategies for advanced gastric cancer. *Semin Surg Oncol.* 2003; 21: 233-248.
8. Glehen O, Mohamed F, Gilly FN. Peritoneal carcinomatosis from digestive tract cancer: new management by cytoreductive surgery and intraperitoneal chemohyperthermia. *Lancet Oncol.* 2004; 5: 219-228.
9. Elias D, Gilly F, Boutitie F. Peritoneal colorectal carcinomatosis treated with surgery and perioperative intraperitoneal chemotherapy: retrospective analysis of 523 patients from a multicentric French study. *J Clin Oncol Off J Am Soc Clin Oncol.* 2010; 28: 63-68.
10. Yan TD, Deraco M, Baratti D. Cytoreductive surgery and hyperthermic intraperitoneal chemotherapy for malignant peritoneal mesothelioma: multi-institutional experience. *J Clin Oncol Off J Am Soc Clin Oncol.* 2009; 27: 6237-6242.
11. Sugarbaker PH. New standard of care for appendiceal epithelial neoplasms and pseudomyxoma peritonei syndrome? *Lancet Oncol.* 2006; 7: 69-76.
12. Gunderson LL, Sosin H. Adenocarcinoma of the stomach: areas of failure in a re-operation series clinicopathologic correlation and implications for adjuvant therapy. *Int J Radiat Oncol Biol Phys.* 1982; 8: 1-11.
13. Wisbeck WM, Becher EM, Russell AH. Adenocarcinoma of the stomach: autopsy observations with therapeutic implications for the radiation oncologist. *Radiother Oncol J Eur Soc Ther Radiol Oncol.* 1986; 7: 13-18.
14. Landry J, Tepper JE, Wood WC, Moulton EO, Koerner F. Patterns of failure following curative resection of gastric carcinoma. *Int J Radiat Oncol Biol Phys.* 1990; 19: 1357-1362.
15. Wils J, Meyer HJ, Wilke H. Current status and future directions in the treatment of localized gastric cancer. *Ann Oncol.* 1994; 5: 69-72.
16. Maruyama K, Okabayashi K, Kinoshita T. Progress in gastric cancer surgery in Japan and its limits of radicality. *World J Surg.* 1987; 11: 418-425.
17. Kaibara N, Sumi K, Yonekawa M, Ohta M, Makino M. Does extensive dissection of lymph nodes improve the results of surgical treatment of gastric cancer? *Am J Surg.* 1990; 159: 218-221.
18. Korenaga D, Moriguchi S, Orita H, Kakeji Y, Haraguchi M. Trends in survival rates in Japanese patients with advanced carcinoma of the stomach. *Surg Gynecol Obstet.* 1992; 174: 387-393.
19. Boku T, Nakane Y, Minoura T, Takada H, Yamamura M. Prognostic significance of serosal invasion and free intraperitoneal cancer cells in gastric cancer. *Br J Surg.* 1990; 77: 436-439.
20. Fujimoto S, Takahashi M, Mutou T, Kobayashi K, Toyosawa T. Improved mortality rate of gastric carcinoma patients with peritoneal carcinomatosis treated with intraperitoneal hyperthermic chemoperfusion combined with surgery. *Cancer.* 1997; 79: 884-891.
21. Koderia Y, Yamamura Y, Shimizu Y. Peritoneal washing cytology: prognostic value of positive findings in patients with gastric carcinoma undergoing a potentially curative resection. *J Surg Oncol.* 1999; 72: 60-65.
22. Bando E, Yonemura Y, Takeshita Y, Taniguchi K, Yasui T. Intraoperative lavage for cytological examination in 297 patients with gastric carcinoma. *Am J Surg.* 1999; 178: 256-262.
23. Fujimura T, Yonemura Y, Ninomiya I, et al. Early detection of peritoneal dissemination of gastrointestinal cancers by reverse-transcriptase polymerase chain reaction. *Oncol Rep.* 1997; 4: 1015-1019.
24. Sethna KS, Sugarbaker PH. New prospects for the control of peritoneal surface dissemination of gastric cancer using perioperative intraperitoneal chemotherapy. *Cancer Ther.* 2004; 2: 79-84.
25. Los G, Mutsaers PH, Lenglet WJ, Baldew GS, McVie JG. Platinum distribution in intraperitoneal tumors after intraperitoneal cisplatin treatment. *Cancer Chemother Pharmacol.* 1990; 25: 389-394.

26. Xu DZ, Zhan YQ, Sun XW, Cao SM, Geng QR. Meta-analysis of intraperitoneal chemotherapy for gastric cancer. *World J Gastroenterol.* 2004; 10: 2727-2730.
27. Yan TD, Black D, Sugarbaker PH. A systematic review and meta-analysis of the randomized controlled trials on adjuvant intraperitoneal chemotherapy for resectable gastric cancer. *Ann Surg Oncol* 2007; 14: 2702-2713.
28. Feingold PL, Kwong MLM, Sabesan A, Sorber R, Rudloff U. Cytoreductive surgery and hyperthermic intraperitoneal chemotherapy for gastric cancer and other less common disease histologies: is it time? *J Gastrointest Oncol.* 2016; 7: 87-98.
29. Yonemura Y, Kawamura T, Bandou E, Takahashi S, Sawa T, Matsuki N. Treatment of peritoneal dissemination from gastric cancer by peritonectomy and chemohyperthermic peritoneal perfusion. *Br J Surg.* 2005; 92: 370-375.
30. Glehen O, Gilly FN, Arvieux C. Peritoneal carcinomatosis from gastric cancer: a multi-institutional study of 159 patients treated by cytoreductive surgery combined with perioperative intraperitoneal chemotherapy. *Ann Surg Oncol.* 2010; 17: 2370-2377.
31. Hall JJ, Loggie BW, Shen P, Beamer S, Douglas Case L. Cytoreductive surgery with intraperitoneal hyperthermic chemotherapy for advanced gastric cancer. *J Gastrointest Surg.* 2004; 8: 454-463.
32. Yu W, Whang I, Chung HY, Averbach A, Sugarbaker PH. Indications for early postoperative intraperitoneal chemotherapy of advanced gastric cancer: results of a prospective randomized trial. *World J Surg.* 2001; 25: 985-990.
33. Glehen O, Passot G, Villeneuve L. GASTRICHIP: D2 resection and hyperthermic intraperitoneal chemotherapy in locally advanced gastric carcinoma: a randomized and multicenter phase III study. *BMC Cancer.* 2014; 14: 183.
34. Sadeghi B, Arvieux C, Glehen O. Peritoneal carcinomatosis from non-gynecologic malignancies: results of the EVOCAPE 1 multicentric prospective study. *Cancer.* 2000; 88: 358-363.
35. Boku N. Gastrointestinal Oncology Study Group of Japan Clinical Oncology Group. Chemotherapy for metastatic disease: review from JCOG trials. *Int J Clin Oncol.* 2008; 13: 196-200.
36. Hirose K, Katayama K, Iida A. Efficacy of continuous hyperthermic peritoneal perfusion for the prophylaxis and treatment of peritoneal metastasis of advanced gastric cancer: evaluation by multivariate regression analysis. *Oncology.* 1999; 57: 106-114.
37. Rossi CR, Pilati P, Mocellin S. Hyperthermic intraperitoneal intraoperative chemotherapy for peritoneal carcinomatosis arising from gastric adenocarcinoma. *Suppl Tumori Off J Soc Ital Cancerol Ai.* 2003; 2: 54-57.
38. Glehen O, Schreiber V, Cotte E. Cytoreductive surgery and intraperitoneal chemohyperthermia for peritoneal carcinomatosis arising from gastric cancer. *Arch Surg Chic Ill 1960.* 2004; 139: 20-26.
39. Scaringi S, Kianmanesh R, Sabate JM, Facchiano E, Jouet P. Advanced gastric cancer with or without peritoneal carcinomatosis treated with hyperthermic intraperitoneal chemotherapy: a single western center experience. *Eur J Surg Oncol.* 2008; 34: 1246-1252.
40. Glehen O, Yonemura Y, Sugarbaker PH. Prevention and treatment of peritoneal metastases from gastric cancer. In: Sugarbaker PH, editor. *Cytoreductive Surgery and Perioperative Chemotherapy for Peritoneal Surface Malignancy: Textbook and Video Atlas.* Woodbury, CT: Cine-Med. 2012; 79-94.
41. Yonemura Y, Fujimura T, Nishimura G, FallaR, Sawa T. Effects of intraoperative chemohyperthermia in patients with gastric cancer with peritoneal dissemination. *Surgery.* 1996; 119: 437-444.
42. Jacquet P, Sugarbaker PH. Clinical research methodologies in diagnosis and staging of patients with peritoneal carcinomatosis. *Cancer Treat Res.* 1996; 82: 359-374.
43. Yang X-J, Huang C-Q, Suo T. Cytoreductive surgery and hyperthermic intraperitoneal chemotherapy improves survival of patients with peritoneal carcinomatosis from gastric cancer: final results of a phase III randomized clinical trial. *Ann Surg Oncol.* 2011; 18: 1575-1581.
44. Yonemura Y, Fujimura T, Fushida S. Hyperthermo-chemotherapy combined with cytoreductive surgery for the treatment of gastric cancer with peritoneal dissemination. *World J Surg* 1991; 15: 530-536.
45. Yonemura Y, de Aretxabala X, Fujimura T. Intraoperative chemohyperthermic peritoneal perfusion as an adjuvant to gastric cancer: final results of a randomized controlled study. *Hepatogastroenterology* 2001; 48: 1776-1782.
46. Glehen O, Mithieux F, Osinsky D. Surgery combined with peritonectomy procedures and intraperitoneal chemohyperthermia in abdominal cancers with peritoneal carcinomatosis: a phase II study. *J Clin Oncol Off J Am Soc Clin Oncol.* 2003; 21: 799-806.
47. Magge D, Zenati M, Mavanur A, Winer J, Ramalingam L. Aggressive locoregional surgical therapy for gastric peritoneal carcinomatosis. *Ann Surg Oncol.* 2014; 21: 1448-1455.
48. Garofalo A, Valle M. Laparoscopy in the management of peritoneal carcinomatosis. *Cancer J.* 2009; 15: 190-195.
49. Badgwell B, Cormier JN, Krishnan S. Does neoadjuvant treatment for gastric cancer patients with positive peritoneal cytology at staging laparoscopy improve survival? *Ann Surg Oncol* 2008; 15: 2684-2691.

50. Valle M, Van der Speeten K, Garofalo A. Laparoscopic hyperthermic intraperitoneal perioperative chemotherapy (HIPEC) in the management of refractory malignant ascites: A multi-institutional retrospective analysis in 52 patients. *J Surg Oncol*. 2009; 100: 331-334.
51. Cunningham D, Allum WH, Stenning SP, Thompson JN, Van de Velde CJ. Perioperative chemotherapy versus surgery alone for resectable gastroesophageal cancer. *N Engl J Med*. 2006; 355: 11-20.
52. Preusser P, Wilke H, Achterrath W. Phase II study with the combination etoposide, doxorubicin, and cisplatin in advanced measurable gastric cancer. *J Clin Oncol Off J Am Soc Clin Oncol*. 1989; 7: 1310-1317.
53. Ajani JA, Ota DM, Jessup JM, Ames FC, McBride C. Resectable gastric carcinoma. An evaluation of preoperative and postoperative chemotherapy. *Cancer*. 1991; 68: 1501-1506.
54. Yonemura Y, Bandou E, Sawa T, Yoshimitsu Y, Endou Y. Neoadjuvant treatment of gastric cancer with peritoneal dissemination. *Eur J Surg Oncol*. 2006; 32: 661-665.
55. Yonemura Y, Bandou E, Kinoshita K, Kawamura T, Takahashi S. Effective therapy for peritoneal dissemination in gastric cancer. *Surg Oncol Clin N Am*. 2003; 12: 635-648.
56. Yonemura Y, Elnemr A, Endou Y, Hirano M, Mizumoto A. Multidisciplinary therapy for treatment of patients with peritoneal carcinomatosis from gastric cancer. *World J Gastrointest Oncol*. 2010; 2: 85-97.
57. Sugarbaker PH. Peritonectomy procedures. *Ann Surg*. 1995; 221: 29-42.
58. Yonemura Y, Fujimura T, Fushida S. Peritonectomy as a Treatment Modality for Patients with Peritoneal Dissemination from Gastric Cancer. In: M.D TN, M.D TY, editors. *Multimodality Therapy for Gastric Cancer*. Springer Japan; 1999; 71-80.
59. Canbay E, Mizumoto A, Ichinose M. Outcome data of patients with peritoneal carcinomatosis from gastric origin treated by a strategy of bidirectional chemotherapy prior to cytoreductive surgery and hyperthermic intraperitoneal chemotherapy in a single specialized center in Japan. *Ann Surg Oncol*. 2014; 21: 1147-1152.
60. Kitayama J, Ishigami H, Yamaguchi H. Salvage gastrectomy after intravenous and intraperitoneal paclitaxel (PTX) administration with oral S-1 for peritoneal dissemination of advanced gastric cancer with malignant ascites. *Ann Surg Oncol* 2014; 21: 539-546.
61. Fujiwara Y, Takiguchi S, Nakajima K, Miyata H, Yamasaki M. Intraperitoneal docetaxel combined with S-1 for advanced gastric cancer with peritoneal dissemination. *J Surg Oncol*. 2012; 105: 38-42.
62. Han DS, Suh YS, Kong SH, Lee HJ, Im SA. Outcomes of surgery aiming at curative resection in good responder to induction chemotherapy for gastric cancer with distant metastases. *J Surg Oncol*. 2013; 107: 511-516.
63. Walker JL, Armstrong DK, Huang HQ. Intraperitoneal catheter outcomes in a phase III trial of intravenous versus intraperitoneal chemotherapy in optimal stage III ovarian and primary peritoneal cancer: a Gynecologic Oncology Group Study. *Gynecol Oncol*. 2006; 100: 27-32.
64. Sugarbaker PH, Bijelic L. Adjuvant bidirectional chemotherapy using an intraperitoneal port. *Gastroenterol Res Pract* Volume 2012; 2012: 5.
65. Culliford AT, Brooks AD, Sharma S. Surgical debulking and intraperitoneal chemotherapy for established peritoneal metastases from colon and appendix cancer. *Ann Surg Oncol*. 2001; 8: 787-795.
66. Glehen O, Kwiatkowski F, Sugarbaker PH. Cytoreductive surgery combined with perioperative intraperitoneal chemotherapy for the management of peritoneal carcinomatosis from colorectal cancer: a multi-institutional study. *J Clin Oncol Off J Am Soc Clin Oncol*. 2004; 22: 3284-3292.
67. Cunliffe WJ. The rationale for early postoperative intraperitoneal chemotherapy for gastric cancer. In: FACS PHSMO, editor. *Management of Gastric Cancer*. Springer US. 1991; 143-159.