

# Usefulness of Endoscopic Ultrasonography in the Diagnosis of Gastric Varices

**Takahiro Sato<sup>1\*</sup>**

<sup>1</sup>Department of Gastroenterology, Sapporo Kosei General Hospital, Sapporo, Japan

**\*Corresponding author:** Takahiro Sato, Department of Gastroenterology, Sapporo Kosei General Hospital, Kita 3 Higashi 8, Chuo-ku, Sapporo 060-0033, Japan, Tel: +81 11 261 5331; Fax: +81 11 261 6040; Email: taka.sato@ja-hokkaidoukouseiren.or.jp

**Published Date:** September 25, 2016

## ABSTRACT

**Objectives:** The aim of this study was to investigate Endoscopic Ultrasonography with Color Doppler (**ECDUS**) findings of gastric varices and to determine the role of ECDUS in the diagnosis of gastric varices.

**Methods:** Two hundred-fifteen patients with gastric varices found consecutively by routine upper endoscopy were evaluated with ECDUS. We monitored the color flow images of gastric varices, para-gastric collateral veins. We measured the blood flow velocity of gastric varices and the wall thickness to submucosal gastric varices with this technique, and investigated the usefulness of ECDUS on evaluating the hemodynamics of gastric varices. Endoscopic findings of gastric varices were evaluated according to the grading system outlined in The General Rules for Recording Endoscopic Findings of Esophago-gastric Varices devised by the Japanese Research Committee on Portal Hypertension.

**Results:** The color flow images of gastric varices and para-gastric veins were delineated in all 215 patients with ECDUS. Evaluation of blood flow velocity in the 215 gastric varices revealed velocities of 7.7-35.7 cm/s (mean, 18.2±6.0 cm/s). We compared velocities of gastric varices with variceal locations and forms. Mean velocity of F3 type gastric varices was 23.7±6.2 cm/s (n=52), while the mean velocity of F2 type gastric varices was 16.7±5.0 cm/s (n=163). The velocities of F3 type gastric varices were significantly higher than those of F2 type (P<0.0001). Mean velocity in the Lg-f cases (n=105) was 17.6±5.4 cm/s, and 18.7±6.1 cm/s in Lg-cf cases (n=110), with no significant difference between Lg-f and Lg-cf cases.

Next, we evaluated the wall thickness to submucosal gastric varices. Two hundred-fifteen of the gastric varices were 0.9-2.2 mm (1.6±0.4 mm) in gastric wall thickness. Mean thickness of Red Color (**RC**) or erosion positive varices was 1.2±0.2 mm (n=42), while the mean thickness of RC or erosion negative varices was 1.7±0.3 mm (n=173). The thickness of RC or erosion positive varices was significantly thinner than that of the negative cases (P<0.0001). Seven cases of the 215 patients had the current history of gastric variceal bleeding, and the other three cases had experienced variceal rupture on follow up (bleeding cases, n=10), and mean thickness of these bleeding cases were 1.1±0.2 mm.

**Conclusion:** ECDUS is a useful modality for the diagnosis of hemodynamics of gastric varices.

**Keywords:** Gastric varices; Endoscopic ultrasonography; Color doppler; Hemodynamics

## INTRODUCTION

Recent technical advances have offered clinicians increasingly greater clarity in visualizing gastric varices. Gastric variceal bleeding is common complication, and it is associated with higher morbidity and mortality rates than hemorrhage from esophageal varices [1]. The Sarin classification of gastric varices divides them into Gastroesophageal Varices (**GOV**) or Isolated Gastric Varices (**IGV**) [2]. Cardiodfundal gastric varices classified as Gastroesophageal Varices type 2 (**GOV2**) or Isolated Gastric Varices 1 (**IGV1**) are more severe and often difficult to treat as compared to the other types of varices.

Hemodynamic studies on gastric varices have been performed worldwide.

Magnetic Resonance (**MR**) and Computed Tomography (**CT**) allow assessment of the entire portal venous system [3,4]. Endoscopic Ultrasonography (**EUS**) has become a useful modality for the diagnosis for esophago-gastric varices, and it is considered most useful in the evaluation of gastric varices [5-7]. On the other hand, several studies have reported the usefulness of EUS with color Doppler (endoscopic color Doppler ultrasonography; ECDUS) in patients with esophageal varices [8-10]. With ECDUS, color flow images of blood vessels can be obtained, and ECDUS allows for more detailed observation of the hemodynamics of esophageal varices than EUS. Previously, Sato et al. reported the usefulness of ECDUS in patients with gastric varices [11].

The aim of this article was to investigate ECDUS findings on gastric varices, including recent data and to determine the clinical role of ECDUS in many cases of gastric varices.

# SUBJECTS AND METHODS

## Patients

Between January 1996 and June 2016, 215 patients with gastric varices found consecutively by routine upper endoscopy were retrospectively evaluated with ECDUS (121 men, 94 women; aged 44-85 yr [mean: 65.2]). The underlying pathologies of portal hypertension included Liver Cirrhosis (**LC**) in 162 patients, cirrhosis associated with Hepatocellular Carcinoma (**HCC**) in 50 patients, and primary biliary cirrhosis in 3 patients (91 Child-Pugh class A type, 92 class B, 32 class C). LC was diagnosed by imaging studies, and diagnosis of HCC was done by imaging and biopsy.

Ten of the 215 gastric variceal patients had previously received emergency or prophylactic Endoscopic Injection Sclerotherapy (**EIS**) for esophageal varices, and twenty-one patients coexisted esophageal varices.

Seven cases of the 215 patients had the current history of gastric variceal bleeding, and the other three cases had experienced variceal rupture on follow up.

## Methods

Hemodynamic evaluation of the gastric varices was performed by ECDUS using a PENTAX FG - 36UX (forward - oblique viewing), 7.5 MHz, convex type, which provided 100o images (convex type ECDUS) or EG-3630UR (forward viewing), 10 MHz, electronic radial type, which provided 270° images (electronic radial type ECDUS) (Pentax Optical, Tokyo, Japan), HITACHI EUB565 or EUB8500 (Hitachi Medical, Tokyo, Japan) was used for the display, respectively. From 2010, newer electronic radial ECDUS was performed using Pentax EG-3670 URK (Pentax, Tokyo, Japan) (forward-view) with a distal tip diameter of 12 mm. This electronic radial array instrument has a curved-array scanning transducer with adjustable frequency (5, 7.5 or 10 MHz) and B mode/color Doppler. A Hitachi EUB 7500 (Hitachi, Tokyo, Japan), which provides 360 degree images, was used for display.

To begin with, identification of gastric varices was performed with B-mode scanning and then, color flow mapping was done. On B-mode scanning, submucosal gastric varices, and para-gastric collateral veins were obtained as hypoechoic vessels within gastric wall or in the tissue and spaces exterior to the adventitia of gastric wall. ECDUS provides a color display of blood flow and evaluates the flow pattern using Fast Fourier Transform (**FFT**) analysis. FFT analysis can indicate the flow pattern and calculate the velocity of blood flow. We monitored the color flow images of gastric varices, and para-gastric or peri-gastric collateral veins. Exploration of gastric variceal flow images was conducted by introducing deaerated water from an autoinfuser device into the stomach through working channel. Velocities were assessed by the pulsed Doppler method, by positioning a sample volume of 1-2 mm in the center of the vessels. The mean velocity of the gastric varices was obtained by averages from a total of two tracings on conspicuous

point of gastric varices. The color gain was adjusted so as to eliminate background noise, and the insonation angle was kept below 60° to minimize ambiguity in measurements of blood flow. We measured the blood flow velocity of gastric varices and the wall thickness to submucosal gastric varices with this technique, and investigated the usefulness of ECDUS on evaluating the hemodynamics of gastric varices.

The study was performed according to the tenets of the Declaration of Helsinki. Written informed consent was obtained from all patients prior to the procedures. The study was approved by the ethical committee of Sapporo Kosei Hospital.

## Endoscopic Findings

Endoscopic findings of gastric varices were evaluated according to the grading system outlined in The General Rules for Recording Endoscopic Findings of Esophago-gastric Varices devised by the Japanese Research Committee on Portal Hypertension [12]. The form (F) of the varices was classified as either small, straight (F1), enlarged tortuous (F2), or large, coil-shaped (F3). Variceal location (L) was classified as: cardiac (Lg-c; located adjacent to the cardiac orifice); fundal (Lg-f; located far from the cardiac orifice); and cardiac and fundal (Lg-cf; located between the cardiac orifice and the fundus). The Red Color sign (RC) referred to dilated, small vessels or telangiectasia on the variceal surface. Mucosal findings of gastric varices were classified into erosion, ulcer, and scar.

One hundred sixty-three patients had F2-type varices and 52 had F3-type. In term of location, 110 patients had Lg-cf varices and 105 had Lg-f. Twenty patients of 215 cases had RC-positive, and 22 patients had erosion on variceal surface.

## Statistical Analysis

Comparisons between two groups were made by Man-Whitney's U-test (non-parametric). A P value of less than 0.05 was considered to be statistically significant. Statistical analysis was performed with the Statview J for Power PC version.

## RESULTS

The color flow images of gastric varices, and para-gastric veins were delineated in all 215 patients with ECDUS. FFT analysis of blood flow in gastric varices showed a continuous wave in 209 of 215 patients and turbulent flow in the remaining patients. Evaluation of blood flow velocity in the 215 gastric varices revealed velocities of 7.7-35.7 cm/s (mean, 18.2±6.0 cm/s).

We compared velocities of gastric varices with variceal locations and forms. Mean velocity of F3 type gastric varices was 23.7±6.2 cm/s (n=52), while the mean velocity of F2 type gastric varices was 16.7±5.0 cm/s (n=163). The velocities of F3 type gastric varices were significantly higher than those of F2 type (P<0.0001). Mean velocity in the Lg-f cases (n=105) was 17.6±5.4 cm/s, and 18.7±6.1 cm/s in Lg-cf cases (n=110), with no significant difference between Lg-f and Lg-cf cases (Table 1).

**Table 1:** Comparison of gastric variceal velocities with ECDUS and endoscopic findings (N=215).

| Gastric varices | ECDUS             |          |
|-----------------|-------------------|----------|
|                 | Velocities (cm/s) | P Value  |
| Form            |                   |          |
| F3              | 23.7±6.2          | P<0.0001 |
| F2              | 16.7±5.0          |          |
| Location        |                   |          |
| Lg-cf           | 18.7±6.1          | NS       |
| Lg-f            | 17.6±5.4          |          |

ECDUS: Endoscopic Color Doppler Ultrasonography

F2: enlarged tortuous large varices

F3: coil-shaped varices

Lg-f: located far from the cardiac orifice

Lg-cf: located between the cardiac orifice and the fundus

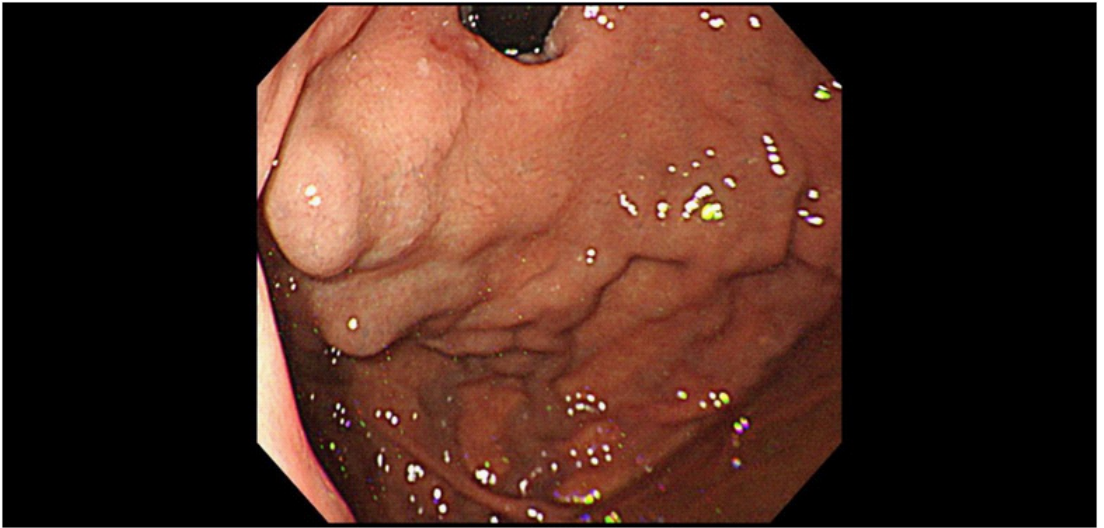
Next, we evaluated the wall thickness to submucosal gastric varices. Two hundred-fifteen of the gastric varices were 0.9-2.2 mm (1.6±0.4 mm) in gastric wall thickness. Mean thickness of RC or erosion positive varices was 1.2±0.2 mm (n=42), while the mean thickness of RC or erosion negative varices was 1.7±0.3 mm (n=173). The wall thickness of RC or erosion positive varices was significantly thinner than that of the negative cases (P<0.0001) (Table 2).

**Table 2:** Comparison of gastric variceal wall thickness with ECDUS and endoscopic findings (N=215).

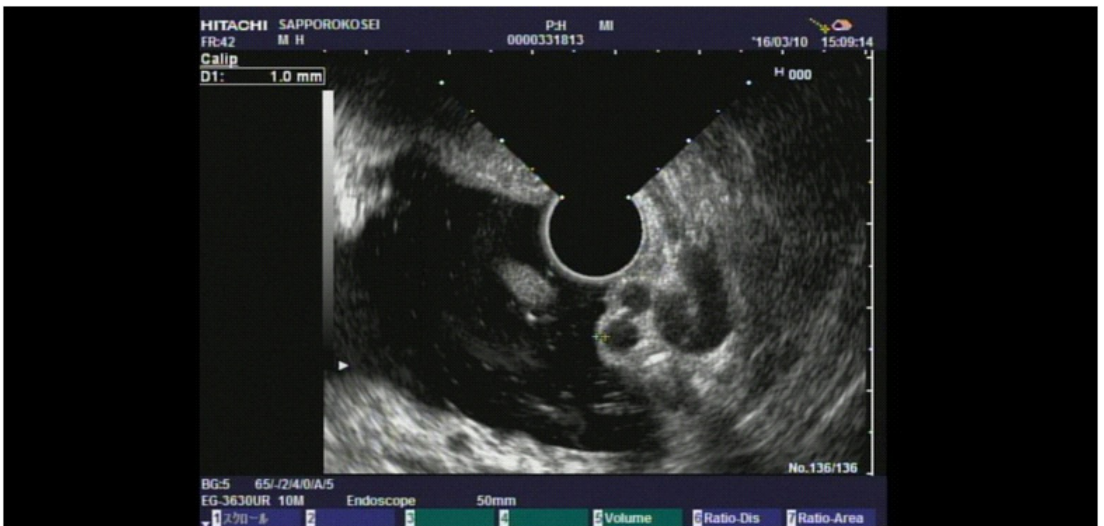| Gastric varices | ECDUS               |          |
|-----------------|---------------------|----------|
|                 | Wall thickness (mm) | P Value  |
| RC or erosion   |                     |          |
| Positive        | 1.2±0.2             | P<0.0001 |
| Negative        | 1.7±0.3             |          |

RC: red color sign

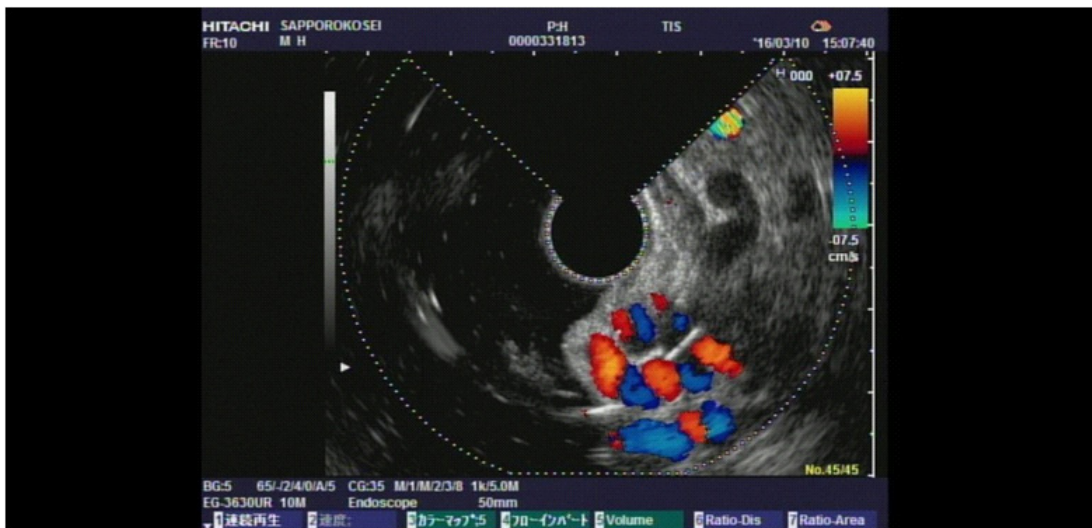
A 64-year-old man with alcoholic liver cirrhosis was admitted to our hospital with tarry stools. Gastric varices of Lg-cf, F2 RC0 in which B-mode scanning showed low echoic vessel images with a wall thickness in 1.0 mm is shown Figure 1a, 1b. Color flow images of gastric varices clearly delineated using ECDUS (Figure 2) and showed a continuous wave with a velocity in 18.0 cm/s with FFT analysis. These gastric varices were diagnosed as high risk for hemorrhage.



**Figure1-a:** Endoscopic findings revealed gastric varices with Lg-cf, F2.



**Figure1-b:** B-mode scanning showed low echoic vessel images in 1.0 mm is shown with a wall thickness.



**Figure 2:** ECDUS provided clear color flow images of blood vessels in gastric varices and showed a continuous wave with a velocity in 18.0 cm/s with fast-Fourier transform analysis.

Seven cases of the 215 patients had the current history of gastric variceal bleeding, and the other three cases had experienced variceal rupture on follow up (bleeding cases, n=10). All 10 cases had the velocities beyond 18 cm/s with ECDUS. Mean thickness of these bleeding cases were  $1.1 \pm 0.2$  mm (0.9-1.3 mm), including 2 RC or erosion-negative case.

## DISCUSSION

Sarin et al. detected gastric varices in 48 (16%) of 309 patients with cirrhosis, non-cirrhotic portal fibrosis and extrahepatic obstruction [13]. In contrast, Watanabe et al reported that the frequency of gastric varices in patients with portal hypertension to be 57% [14]. Korula, et al reported on two distinct subsets of gastric varices, detected endoscopically: junctional varices and fundal varices [15]. Endoscopy has a very sensitive predictive value for variceal hemorrhage [16]. However, there are few cases of RC positive gastric varices and it is difficult to diagnose the high risk for bleeding on gastric varices. Still more, endoscopy is a limited modality for detecting gastric varices, given how deep the submucosal or extramural collateral veins of gastric varices are. MR and CT allow assessment of the entire portal venous system. Willmann et al have demonstrated that multi-detector row CT angiography is equivalent to EUS in the detection of fundal varices [17].

The introduction of EUS equipped with Doppler facilities has allowed the sonographic visualization of vessels and the evaluation of vascular blood flow along with morphology in the diagnosis of gastric varices [18,19]. ECDUS can also calculate the velocity by an FFT analysis. Sato et al. monitored color flow images, and measured the velocity of gastric varices and the wall thickness of submucosal gastric varices. ECDUS is superior to CT for measurement of blood flow

velocity of gastric varices as well as wall thickness of submucosal gastric varices, suggesting that these determinations obtained by ECDUS are useful for the prediction of variceal bleeding [11]. Iwase et al. reported that ECDUS is a useful method for evaluating gastric varices and endoscopic obliteration with cyanoacrylate glue [20]. In addition, Imamura et al. measured the variceal blood flow volume using echo-endoscopy and investigated the correlations between the blood flow volume and gastric variceal diameter, and found the strong correlation between the blood flow volume and gastric variceal diameter [21]. In generally, the blood flow volume is high when blood flow velocity is rapid.

In this article, we monitored color flow images, and measured the velocity of gastric varices and the wall thickness to submucosal gastric varices. Results of this study show the velocity of gastric variceal blood flow of F3 type varices to be significantly higher than that of F2 type, and all ten bleeding cases had the velocities beyond 18 cm/s with ECDUS. The wall thickness of RC or erosion positive varices was significantly thinner than that of the negative cases. Mean wall thicknesses of bleeding cases were  $1.1 \pm 0.2$  mm, including 2 RC or erosion-negative case. Our results suggest that the measurements of blood flow velocity in gastric varices and wall thickness of gastric varices by ECDUS are useful for the prediction of variceal bleeding.

The diagnosis of high risk gastric varices is a very important because of high morbidity and mortality of gastric variceal bleeding. The present study provides the usefulness of ECDUS for the diagnosis of gastric varices.

In conclusions, ECDUS is a useful modality for the diagnosis of hemodynamics of gastric varices.

## References

1. Trudeau W, Prindiville T. Endoscopic injection sclerosis in bleeding gastric varices. *Gastrointest Endosc* 1986; 32: 264-268.
2. Sarin SK, Lahoti D, Saxena SP, Murthy NS, Makwana UK. Prevalence, classification and natural history of gastric varices: a long-term follow-up study in 568 portal hypertensive patients. *Hepatology* 1992; 16: 1343-1349.
3. Cho KC, Patel YD, Wachsberg RH, Seeff J. Varices in portal hypertension: Evaluation with CT. *Radiographics*. 1995; 15: 609-622.
4. Sato T, Yamazaki K, Toyota J, Karino Y, Ohmura T, et al. Evaluation of magnetic resonance angiography in detection of gastric varices. *J Gastroenterol*. 1999; 34: 321-326.
5. Boustiere C, Dumas O, Jouffre C, Letard JC, Patouillard B, et al. Endoscopic ultrasonography classification of gastric varices in patients with cirrhosis. Comparison with endoscopic findings. *J Hepatol*. 1993; 19: 268-272.
6. Caletti GC, Brocchi E, Ferrari A, et al. Value of endoscopic ultrasonography in the management of portal hypertension. *Endoscopy*. 1992; 24: 342-346.
7. Sanyal AJ. The value of EUS in the management of portal hypertension. *Gastrointest Endosc*. 2000; 52: 575-577.
8. Sato T, Yamazaki K, Toyota J, et al. Visualization of palisade veins in esophageal varices by endoscopic color Doppler ultrasonography. *Dig. Endosc* 2003; 15: 87-92.
9. Sato T, Yamazaki K, Toyota J, Karino Y, Ohmura T, et al. Evaluation of hemodynamics in esophageal varices: Value of endoscopic color Doppler ultrasonography with a galactose - based contrast agent. *Hepatol Res*. 2003; 25: 55-61.
10. Sato T, Yamazaki K, Toyota J, Karino Y, Ohmura T, et al. Usefulness of electronic radial endoscopic color Doppler ultrasonography in esophageal varices: comparison with convex type. *J Gastroenterol*. 2006; 41: 28-33.
11. Sato T, Yamazaki K, Toyota J, Karino Y, Ohmura T, et al. Observation of gastric variceal flow characteristics by endoscopic ultrasonography using color Doppler. *Am J Gastroenterol*. 2008; 103: 575-580.



12. Idezuki Y. General rules for recording endoscopic findings of esophagogastric varices. *World J Surg.* 1995; 19: 420-422.
13. Sarin SK, Nanda R, Sachdev G. Follow-up of patients after variceal eradication: A comparison of patients with cirrhosis, non-cirrhotic portal fibrosis and extrahepatic obstruction. *Ann Surg* 1986; 204: 78-82.
14. Watanabe K, Kimura K, Matsutani S, Ohto M, Okuda K. Portal hemodynamics in patients with gastric varices. A study in 230 patients with esophageal and/or gastric varices using portal vein catheterization. *Gastroenterology.* 1988; 95: 434-440.
15. Korula J, Chin K, Ko Y, Yamada S. Demonstration of two distinct subsets of gastric varices. Observation during a seven-year study of endoscopic sclerotherapy. *Dig Dis and Sci.* 1991; 36: 303-309.
16. Beppu K, Inokuchi K, Koyanagi N, Nakayama S, Sakata H, et al. Prediction of variceal hemorrhage by esophageal endoscopy. *Gastrointest Endosc.* 1981; 27: 213-218.
17. Willmann JK, Weishaupt D, Böhm T, Pfammatter T, Seifert B, et al. Detection of submucosal gastric fundal varices with multi-detector row CT angiography. *Gut.* 2003; 52: 886-892.
18. Kohler B, Riemann JF. The role of endoscopic Doppler-sonography. *Hepatogastroenterology.* 1999; 46: 732-736.
19. Sgouros SN, Bergele C, Avgerinos A. Endoscopic ultrasonography in the diagnosis and management of portal hypertension. Where are we next?. *Dig Liver Dis.* 2006; 38: 289-295.
20. Iwase H, Suga S, Morise K, et al. Color Doppler endoscopic ultrasonography for the evaluation of gastric varices and endoscopic obliteration with cyanoacrylate glue. *Gastrointest Endosc.* 1995; 41: 150-154.
21. Imamura H, Irisawa A, Shibukawa G, Takagi T1, Hikichi T, et al. Echo-endoscopic analysis of variceal hemodynamics in patients with isolated gastric varices. *Endosc Ultrasound.* 2014; 3: 238-244.