

# Current Role of Laparoscopic Radical Cystectomy in the Treatment of Bladder Cancer

**Juan Gómez Rivas<sup>1,2\*</sup>, Mario Álvarez-Maestro<sup>1,2</sup>, Diego M Carrion<sup>1</sup>, Alfredo Aguilera<sup>1,2</sup>  
and Luis Martínez Piñeiro<sup>1,2</sup>**

<sup>1</sup>Department of Urology, La Paz University Hospital, Spain

<sup>2</sup>Instituto de investigación Hospital Universitario La Paz (IdiPAZ)

**\*Corresponding author:** Juan Gómez Rivas, Department of Urology, La Paz University Hospital, Madrid, Spain, Paseo de la Castellana 261; Tel: + 34 917 277 305, Fax: +34 917 277 070; Email: juangomezr@gmail.com

**Published Date:** January 30, 2018

## INTRODUCTION

Radical cystectomy (**RC**) is the gold standard treatment for muscle-invasive bladder cancer (**MIBC**); BCG-unresponsive and non-muscle invasive high-risk bladder cancer (**NMIBC**). Traditionally, RC has been performed using an open approach (**ORC**) [1].

ORC is associated with significant morbidity and mortality, even at high-volume centers [2]. Minimally invasive approaches to RC (i.e., laparoscopic and robot-assisted) are used in order to improve preoperative outcomes, decrease hospital length stay (**LOS**) and minimize complications [3].

The first case described of laparoscopic cystectomy was reported in 1992 by Parra et al. [4], when they performed simple cystectomy for a 27 years old female with post-traumatic paraplegia complicated with benign pyocystis and acute urinary retention after urinary diversion. In 1993, Sanchez de Badajoz et al. published a case report on the use of laparoscopic radical cystectomy (**LRC**) and ileal conduit technique for bladder cancer (**BC**) [5]. In 2000, Gill et al. published the first two cases of laparoscopic radical cystoprostatectomy with ileal conduit performed completely intra corporeally [6]. In 2001, Türk et al. published the first LRC procedure with continent urinary diversion (**UD**) performed completely intra corporeally [7]. However, due to its prolonged

learning curve and demand for advanced laparoscopic skills, LRC was not adopted by most urological surgeons. Robotic technology, with enhanced ergonomics, decreased the requirement for advanced laparoscopic technical skills and allowed more surgeons to safely perform minimally invasive radical cystectomy (**MIRC**). Despite the success with MIRC, its wide usage remains a matter of debate because the lack of large randomized and prospective trials comparing the long-term outcomes and oncologic results between the two modalities (ORC versus MIRC).

Almost 50% of patients who undergo ORC will have a tumor recurrence in the following 5 years, while the 5-year survival rates have been reported to range between 73% - 89% in organ-confined disease, reducing to 45% to 55% in patients with extravesical disease and 25% to 35% with nodal involvement [8-10]. These results are also reported in LRC series with short-term oncologic outcomes [11]. The complication rate of ORC is in the range of 40% to 65% with a transfusion requirement of around 66%, while the major complication rates range between 10% and 12% with a mortality of 2% to 3% [8,9]. LRC can also provide an advantage of less blood loss, analgesic requirement, reduced scarring, and fewer complications [12-14].

## **BLADDER CANCER EPIDEMIOLOGY**

BC is the 7th most commonly diagnosed cancer in male population worldwide, whilst it drops to 11th when both genders are considered. The worldwide age-standardized incidence rate (per 100,000 person/years) is 9.0 for men and 2.2 for women. In the European Union, the age-standardized incidence rate is 19.1 for men and 4.0 for women [15].

In Europe, the highest age-standardized incidence rate has been reported in Belgium (31 in men and 6.2 in women) and the lowest in Finland (18.1 in men and 4.3 in women). Worldwide, the BC age-standardized mortality rate (per 100,000 person/years) was 3.2 for men vs. 0.9 for women in 2012 [15]. BC incidence and mortality rates vary across countries due to differences in risk factors, detection and diagnostic practices, and availability of treatments. The variations are however partly caused by the different methodology used in the studies and quality of data collection. The incidence and mortality of BC has decreased in some registries, possibly reflecting the decreased impact of causative agents [16].

Approximately 75% of patients with BC present with a disease confined to the mucosa (stage Ta, carcinoma *in situ* [**CIS**]) or sub mucosa (stage T1). They have a high prevalence due to long-term survival in many cases and lower risk of cancer-specific mortality compared to T2-4 tumours [1].

## **LAPAROSCOPIC RADICAL CYSTECTOMY: SURGICAL TECHNIQUE**

RC consists in two consecutive surgical procedures. First, is the extirpative part, which can be performed in an open or minimally invasive fashion and includes removal of the urinary bladder and pelvic LN, along with the prostate and seminal vesicles (in men) or the uterus, cervix, oviducts and ovaries (in females). Second part includes the reconstructive aspect, where a

piece of small and/or large bowel is isolated from the gastrointestinal tract and used to perform a urinary reservoir. UD can be performed either using open (extracorporeal [ECUD]) or intra corporeal (ICUD) approach. Most of the surgeons perform an extra/intra corporeal (hybrid) approach to UD, where the isolation of the bowel segment, re-establishment of bowel continuity, fashioning of the urinary reservoir and uretero intestinal anastomosis (UIA) are performed extra corporeally through a minilaparotomy incision, while the reservoir-urethral anastomosis is performed intra corporeally after closure of the minilaparotomy incision and re-establishment of pneumoperitoneum.

LRC has been performed in our department since 2005. The following surgical description is from authors experience after > 10 years.

## Surgical Preparation

Nowadays, we apply the Enhanced Recovery After Surgery program (ERAS) or “fast-track” program, which has become the basis of perioperative management after colorectal surgery, vascular, thoracic, and more recently RC [17-20]. These programs attempt to modify the physiological and psychological responses to major surgery contributing in the reduction of postsurgical complications and hospital stays and improving the cardiopulmonary and bowel function after surgery resulting in a faster recovery of patients. The principles of ERAS protocol include: information and advice prior to surgery to the patient, preoperative nutrition, avoiding prolonged fasting, perioperative carbohydrate loading 2 hours prior to surgery, standardized anesthetic and analgesic techniques (epidural analgesia and nonopioid), and early mobilization. Table 1 summarizes the modified ERAS protocol used in our institution.

**Table 1:** Modified ERAS protocol used at La Paz University Hospital.

<b>PREOPERATIVE</b>	
1.	Preadmission counselling
2.	Fluid and carbohydrate loading: 2 sugar teaspoons in clear liquids 8 and 2 hrs before surgery.
3.	No prolonged fasting: Solid food intake up to 8 hrs before surgery and liquids up to 2 h before anesthetic induction.
4.	No selective bowel preparation: Only a fleet enema is used the day before surgery.
5.	Antibiotic prophylaxis: Amoxiciline clavulanate 2 grs 30 minutes before anesthetic induction.
6.	Thromboprophylaxis: Bemiparin 3.500 IU subcutaneous 12 hrs before surgery, maintained until 15 days to 1 month post surgery.
<b>INTRAOPERATIVE</b>	
1.	Short-acting anesthetic agents
2.	Epidural anesthesia/analgesia
3.	Maintenance of normothermia: body warmer.
4.	Maintenance of normovolemia
<b>POSTOPERATIVE</b>	
1.	No nasogastric tube
2.	No parenteral nutrition
3.	Use of prokinetic agents: Metoclopramide 10 mgs each 8 hrs.
4.	Early oral nutrition: the first or second day after surgery only water. Then the progression of the diet depends on the evolution of each patient.
5.	Avoid opioid analgesia
6.	Early mobilization
7.	Usage of chewing gum

## Surgical Approach. Cystectomy

After general anesthesia, the patient is placed in a 30 degrees Trendelenburg position (Figure 1); an indwelling bladder catheter is inserted using sterile technique. When the patient is on the operating table, bilateral leg bandages are applied and then are removed on the first postoperative day. For placement of the first port for the 0 degrees lens, a small incision is made 3-4 cm supraumbilically until the peritoneal cavity is reached. After insufflations of CO<sub>2</sub> to a pressure of 14mm Hg, the other three trocars (four in total) are inserted under visual guidance, placing one 10-mm trocar suprapubically and two 5 mm trocars in the right and left iliac fossa.

An incision is made in the parietal peritoneum at the level of the iliac crossing until the ureter is identified at this level. We continue opening the peritoneum with an H-shaped incision until the umbilical arteries are viewed on both sides and towards the Douglas cul de-sac to dissect the vasa differentia and seminal vesicles, starting dissection of the posterior prostatic wall after opening Denonvilliers fascia. The laterovesical spaces are developed until the endopelvic fascia and then the umbilical arteries are dissected, clipped, and transected. The ureters are dissected down to their entry into the bladder, where they are clipped and cut. Control of the bladder vascular pedicle is then performed by ligation with 10-mm clips. At the end of this step, dissection and vascular control of the vas differentia and seminal vesicles is complete. Vascular control of the prostatic pedicles is then initiated after opening the endopelvic fascia bilaterally.

Next, the urachus is coagulated and sectioned to allow access to the space of Retzius. The fact that the bladder remains fixed until this time avoids the need for an additional port to apply traction to the bladder and allows the surgeon to work more comfortably. With the aid of a bipolar forceps, the venous complex of Santorini is controlled, which is divided without the need for a stitch. After performing dissection of the prostate apex and urethra, attempting to retain the maximum length of urethra in case a neobladder is performed for urinary diversion, the bladder catheter is removed and the urethra is cut distally to a Hem-o-lok® clip placed on the urethra. This avoids the possible spread of tumour cells [20].

At this point, lymph node dissection (**LND**) is performed. The extent of LND has not been established to date. Standard LND in BC patients involves removal of nodal tissue cranially up to the common iliac bifurcation, with the ureter being the medial border, and including the internal iliac, presacral, obturator fossa and external iliac nodes. Extended lymphadenectomy includes all lymph nodes (**LN**) in the region of the aortic bifurcation, and presacral and common iliac vessels medial to the crossing ureters. The lateral borders are the genitofemoral nerves, caudally the circumflex iliac vein, the lacunar ligament and the lymph node of Cloquet, as well as the area described for standard lymphadenectomy. A super-extended lymphadenectomy extends cranially to the level of the inferior mesenteric artery [1].

It has been suggested that progression-free survival as well as overall survival might be correlated with the number of LN removed during surgery, although there are no data from randomized trials on the minimum number of LN that should be removed. Nevertheless, survival rates increase with the number of dissected LN. Removal of at least 10 LN has been postulated as sufficient for evaluation of LN status, as well as being beneficial for overall survival in retrospective studies [21-23].

## **Surgical Approach. Urinary Diversion**

The techniques of ECUD have been extensively discussed in the literature and will not be commented on this chapter. Only the published techniques of ICUD will be explained. Most minimally invasive UD series described the use of ileum as the preferred intestinal segment to perform UD, and have shown that all steps of ECUD can be done completely intra corporeally.

### **Left ureteral transposition & isolation of the bowel segment**

ICUD starts by the transposition of the left ureter under the sigmoid mesentery and isolation of the ileum, taking care to stay far from the ileocecal valve by a minimum of 15-20 cm. For ileal conduit (**IC**), 15-20 cm is enough length, meanwhile for othotopic neobladder (**ONB**) the isolated ileal segment is longer, for example 50-65 cms for Studer ONB. In ORC, transillumination is used to identify mesenteric blood vessels and select the adequate segment, whereas in ICUD this step has been omitted in most series. One series reported a novel method for intra corporeal transillumination using fluorescence-enhanced imaging and intravenous indigo-cyanine green

[24]. Whether omitting transillumination has any significant adverse outcomes on the viability of the intestinal reservoir or on bowel-related complications is unknown since most UD related complications are multifactorial. Potential complications from omitting transillumination may include mesenteric hematoma and reservoir ischemia/necrosis.

Mesenteric windows are created on both sides of the ileal segment of choice using a combination of cautery, the Endo GIA™ stapler or the LigaSure™ device (Covidien, MA, USA) depending on surgeon preference. The future ileal segment is isolated using the 60 mm Endo GIA stapler on both ends. Some series have described approximating the two ileal ends together using a silk suture to prevent malrotation and ensure proper orientation. A laparoscopic sucker is used to wash out the isolated ileal segment through a small enterotomy [25].

### **Creation of the intracorporeal ileal conduit**

The three main subsequent steps are re-establishment of bowel continuity, UIA and stoma fashioning. These steps can be performed in any order, depending on surgeon preference. The early series of laparoscopic ICIC re-established bowel continuity first, followed by stoma fashioning and UIA [27]. Those series demonstrated prolonged operative time (**OT**) and difficulties in bowel irrigation and UIA, which resulted in a high complication rate. In the robotic era, all series describe stoma maturation at the end of the procedure. Stoma maturation before the UIA can interfere with the maneuverability of the conduit and make subsequent UIA challenging. Some series re-established bowel continuity first, while others performed the UIA first [26,27].

### **Ureteroileal anastomosis**

UIA can be performed using Bricker or Wallace techniques and requires ureteral spatulation using cold scissors for 2-3 cms [28]. An enterotomy is made at the proximal part of the IC, using cold scissors. Absorbable interrupted or running Van Velthoven-type sutures are used to sew the ureteral ends to ileum. After the posterior wall of the UIA is made, single J stents are passed through the full length of the IC and across the UIA with the aid of laparoscopic sucker. The use of chromic sutures to secure each stent to the conduit has been described by some authors [26]. Subsequently, the anterior wall of the UIA is completed.

### **Restoration of bowel continuity**

To re-establish bowel continuity, one enterotomy is made at the antimesenteric border of each ileal end to accommodate the blades of the Endo GIA stapler. Re-establishment of bowel continuity is made in a side-to-side fashion. After the first staple load is fired, a second load is fired across the two open ends of the now-connected ileal limbs to seal the intestinal lumen. Several reinforcement stitches are placed between the two ileal ends and the mesenteric window is closed. A passive drain is left in the vicinity of the conduit [29].

## Stoma maturation

Finally, stoma maturation is performed in a standard fashion.

## Creation of intra corporeal continent reservoirs

Minimally invasive creation of a continent reservoir follows the principles of open surgery. Most series of MIRC and continent ICUD performed the Studer ONB [25,30,31]

The key step in fashioning the Studer reservoir entails identification of a sufficiently mobile distal ileal segment that can reach the urethral stump. Once that is done, a small opening is made on the antimesenteric border of that segment and is sewn to the urethral stump with running or interrupted sutures over a 20-F urethral catheter. Subsequently, a 50-cm ileal segment is isolated using the Endo GIA stapler (10 cm distal and 40 cm proximal to the ileourethral anastomosis). After re-establishment of bowel continuity using the Endo GIA stapler, cold scissors are used to open the antimesenteric border of the entire ileal segment. The ileal segment is folded into a U shape and a running absorbable suture is used to sew the posterior and distal anterior walls of the reservoir in a seromuscular fashion. The ureters are spatulated 2-3 cm and the UIA is started according to surgeon preference (Bricker or Wallace) using interrupted or running sutures. Single J stents are passed through the lower anterior abdominal wall into the reservoir and across the UIA, which is now completed. The remainder of the anterior wall of the reservoir is closed. A passive drain is left in the vicinity of the reservoir.

## Technique variants. Nerve sparing and pelvic organ preservation

Different approaches have been described to improve voiding and sexual function in patients undergoing RC for BC. No consensus exists regarding which approach preserves function best. Concern remains regarding the impact of “sparing-techniques” on oncological outcomes [32-35].

Four main types of sexual-preserving techniques have been described:

1. **Prostate sparing cystectomy (PSC):** part or the whole prostate is preserved including seminal vesicles, vas deferens and neurovascular bundles.
2. **Capsule sparing cystectomy:** the capsule or peripheral part of the prostate is preserved with adenoma (including prostatic urethra) removed by TURP or en bloc with bladder. Seminal vesicles, vas deferens and neurovascular bundles are also preserved.
3. **Seminal sparing cystectomy:** seminal vesicles, vas deferens and neurovascular bundles are preserved
4. **Nerve sparing cystectomy:** the neurovascular bundles are the only tissue left in place.

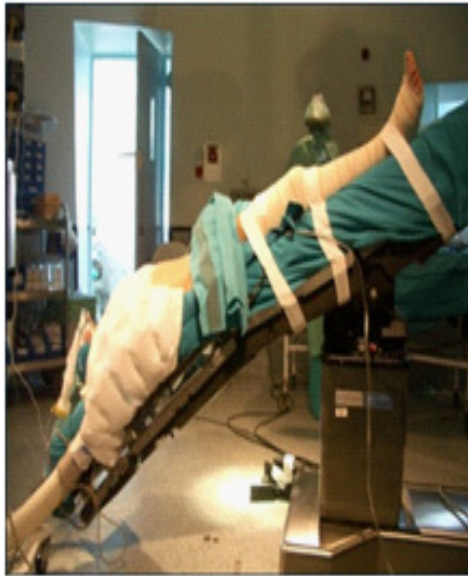
The majority of the studies included patients who were potent pre-operatively with organ-confined disease without tumour in the bladder neck and/or prostatic urethra. Prostate cancer was ruled out in all of the SPC techniques, except in those performing nerve-sparing cystectomy.

## Our experience [35]

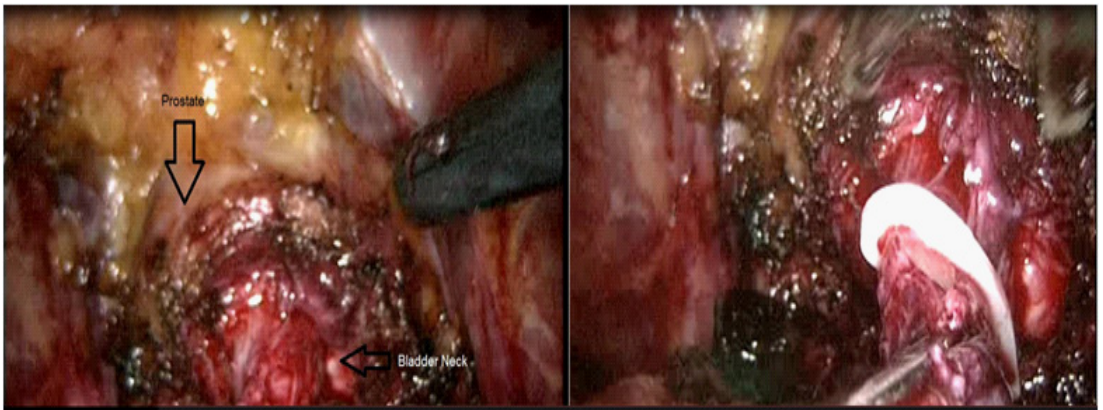
In 2008, we introduced a modified technique of LRC in which the prostatic capsule is spared in selected patients with BC. All patients included for this technique referred good sexual function prior to surgery defined by having erections with successful intercourse with sexual stimulation. They had either pathologically confirmed MIBC (clinically T2N0Mx/0), or NMIBC recurrent after BCG. A complete physical examination, complete blood analysis, and computerized tomography (CT) was done. Patients had a normal digital rectal examination and prostate specific antigen (PSA) less than 4 ng/ml. Patients with >T2 / N+ BC (clinically or in CT), carcinoma *in situ*, tumors next to the bladder neck, bad prognosis pattern (for example epidermoid carcinoma), palpable nodule(s) in the prostate, and/or high PSA (>4 ng/ml) were excluded.

Like any laparoscopic pelvic surgery, the patient is placed in forced Trendelenburg position (Figure 1). After the development of pneumoperitoneum, four ports are placed, two 10 mm and two 5 mm. The peritoneum is incised at the iliac crossing level, and we continue the incision over the external iliac artery to the internal inguinal ring and caudally to the Douglas pouch. The vas deferentia are consecutively identified, and the superior bladder arteries and both ureters are dissected. Both vas deferentia are released and at the opening of the Douglas pouch, the front and top face of both seminal vesicles are released. After clipping and section of the superior bladder arteries and both ureters, the bladder pedicle is dissected with the help of monopolar tip sealer. Later, Retzius space is developed and frees the bladder completely. Then, we proceed to a careful dissection of the bladder neck in the same way as in laparoscopic radical prostatectomy, reaching the level of the seminal vesicles previously developed (Figure 2). After completely dissecting the bladder neck with cuff enough, we proceed to put a hem-o-lock 10 mm and section it; in that way, we guarantee the integrity of the complete bladder, avoiding any risk of tumour dissemination. After releasing the cystectomy specimen, we immediately proceed to the bagging. Then, LND is done as previously described. Finally, we proceed to perform the prostatic adenectomy (Figure 3). The cleavage plane is easily identified because the bladder is not present in the surgical field. Finally, we perform a thorough review of hemostasis and do a laparotomy to perform the intestinal time (7-10 cm long). We proceed to select the intestinal loop and rebuild intestinal transit, the performance of the neobladder, and perform reimplantation of both ureters. When the neobladder is finished, it is reintroduced into the abdominal cavity, pneumoperitoneum is redone after the closure of the laparotomy, and we proceed to the prostatic capsule-neobladder anastomosis (Figure 4). Monocryl 3/0 is used and we perform a continuous suture that starts from the right lateral side of the prostate capsule and urethra to the posterior face of the prostate capsule anastomosing it to the urethra. After the posterior face is performed, the anterior face is done, similar to what is done in radical prostatectomy. Unlike others' neobladder-urethral anastomosis, in some cases it may be necessary to start with another continuous suture for the anterior face to join the posterior face suture [35].

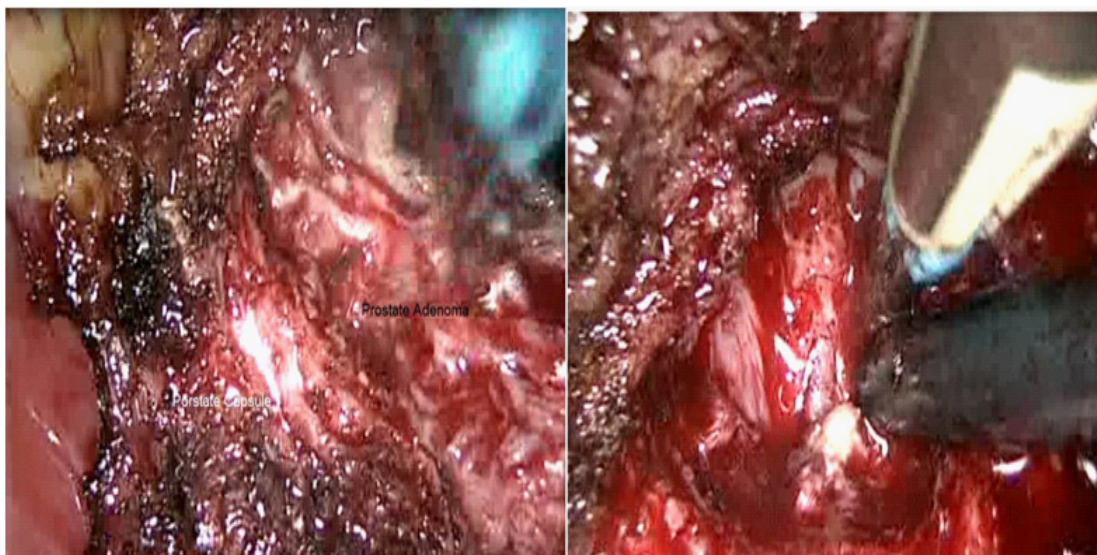




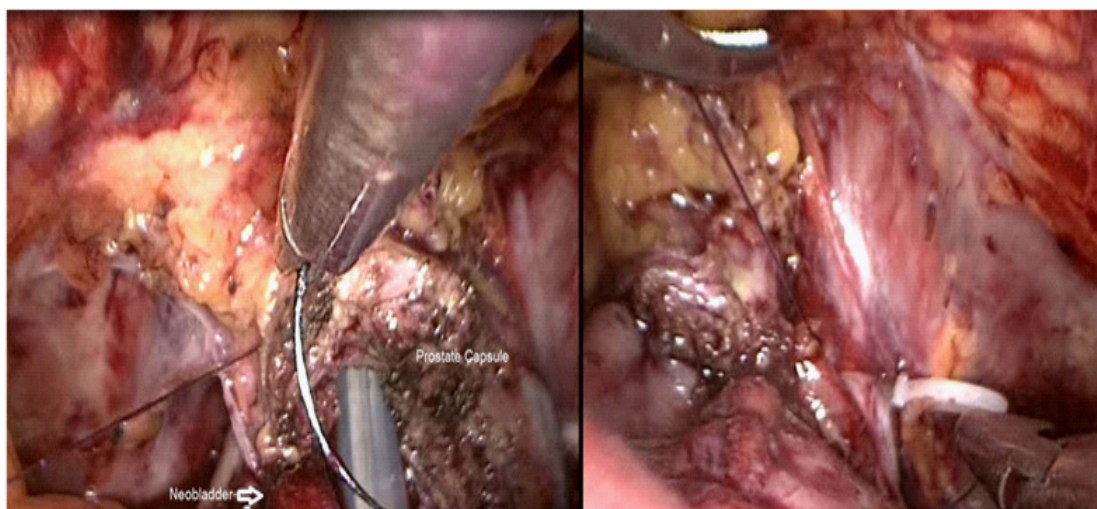
**Figure 1:** Trendelenburg position for laparoscopic radical cystectomy.



**Figure 2:** Bladder neck dissection and hem-o-lock placement.



**Figure 3:** Left: Prostatic adenoma dissection. Right: Prostate capsule.



**Figure 4:** Prostate capsule - neobladder anastomosis.

## Controversies with prostate capsule sparing techniques. Oncological aspects

In 2002, Vallencien et al. [32] published their 10-year follow-up results of 100 patients who had PSC in their centre. Although the functional results were very promising, the lack of a long-term follow-up (81 patients were followed for only 12 months) together with a high incidence of distant metastasis was disappointing.

Despite these results, several groups have published outcomes using PSC in patients with BC. It is essential to note, that all these studies vary widely in several critical aspects of study design.

Only a few series limited prostate-sparing to patients with clinically organ-confined urothelial disease (cT2), with some groups including clinical T3/T4 disease [36]. Age limits for PSC also varied, with some studies including men into their 8th decade, increasing the likelihood of both occult prostate cancer and preoperative erectile dysfunction, thereby decreasing the likelihood of functional benefit from prostate sparing [36]. Screening protocols for occult prostatic malignancy also vary widely, with no consensus presented for this crucial aspect of preoperative risk assessment.

Cystoprostatectomy specimens obtained from patients with BC provide a unique opportunity to assess the features of silent prostate cancer (PC). The frequency of incidentally discovered PC in these specimens is extremely variable, ranging from 4% to 60% [37,38]. This variability may be explained by several factors, including different pathology sampling techniques.

The incidence of urothelial carcinoma of the prostate ranges from 12% to 48% in cystectomy specimens with stromal invasion present in 7.6-16.6% [39]. However, under-reporting of prostatic involvement is common because most studies lack careful pathologic assessment of the prostate.

The primary goal of laparoscopic PSC for BC in our series is to optimize postoperative functional results for continence and sexual function while always preserving the oncological principles. Continence rates following PSC are impressive in most series [40-42]. Nonetheless, it must be noted that validated questionnaires were not routinely used to assess continence or potency in the majority of the literature. The effect of PSC on sexual function is a rarely investigated matter. The recovery rate of erectile function ranges from 14-100% using a nerve-sparing technique with or without saving the prostate [40-42].

Prostate-sparing cystectomy remains one of the most controversial topics in urology. A population of relatively young, otherwise healthy men with good erectile function and high risk NMBC who might be resistant to RC would be the ones most likely to benefit from PSC, presuming that these critically important oncologic concerns may be properly addressed.

## **SURGICAL OUTCOMES**

### **Patient selection criteria**

Due to data limitations, until recently, MIRC was considered as investigational procedures for which no advantages could be shown as compared to ORC. Most of the available studies suffered from patient selection bias (age, stage) [1]. As a novel technique emerges, it is natural and appropriate to select favorable patients to try and ensure patients' safety and optimal outcomes. Many surgeons performing LRC tend to select patients who are generally with a young age, a suitable BMI and a good co-morbidity profile early in their series and typically offer the procedure to patients with organ-confined BC. These favorable selection criteria would also induce those patients a more quick recovery from ORC with a lower probability of transfusion and other complications. A recent meta-analysis showed very good baseline characteristics with no

significant difference regarding to age, gender, BMI, history of previous surgery, clinical stage or diversion type; however, this meta-analysis found a lower ASA score in LRC but with a significant publication bias [11].

Regarding patient's age, RC in elderly patients is a controversial issue that has noticed an increase in importance overtime because of the lengthening average life span. A comparative study from this authors over 180 patients who underwent LRC revealed that the group of patients <70 years had less co-morbidities when compared with the group >70 years, complications were similar and mean hospital length of stay was not significantly different between the groups, so we concluded that LRC in the elderly patient may be offered as a treatment option in selected patients [43].

Since there is a continuous flow of reports on MIBC, the current recommendations and status of MIBC as experimental will be subject to changes in the coming years

## Analgesia requirements

Different series have evaluated the narcotic analgesic requirement for LRC and ORC, which shows less narcotic analgesic requirement in LRC indicative of less pain, an earlier recovery of bowel function and return to normal activity. Aghazadeh et al. speculated that this might be caused by prolonged abdominal retraction and longer incision during ORC [44]. Less postoperative pain and the decreased narcotic analgesic requirement result in early recovery of bowel function and ambulation.

## Blood loss

One of the benefits described in MIRC is less blood loss and reduced risk of preoperative blood transfusion (**PBT**), which may be partly due to better exposure of surgery fields provided by the minimally invasive surgery. A lower PBT rate may reflect lower complications, with a consequent decrease in blood transfusion needs, shorter time to ambulation and shorter time to regular diet. Moreover, patients received LRC got discharged earlier than those received ORC [11].

The comprehension of clinical oncology, tumour biology and immunology has advanced impressively. Nowadays, is known that several mechanisms might promote metastasis after surgery including the postoperative immuno suppression; this issue has been well analyzed by Shakhar et al., also the immunosuppressive effect of blood transfusion has been described in the 70s decade in a report of enhanced renal allograft survival among patients receiving a transfusion [45-47].

There are different studies in the last decades focused on general surgery patients and the impact of PBT in cancer patients' survival, and most of them have supported an independent association between PBT and worse survival in those with solid tumour malignancies. PBT has been independently associated with mortality in patients after surgery for gastric cancer, hepatocellular carcinoma, lung cancer, colorectal cancer and recently BC [48-51].

ORC is associated with a high PBT rate, ranging around 30% in different series [2], but there are a few studies evaluating the relationship between transfusion and survival after this procedure [52,53]. In our institution, we performed a retrospective study analyzing 218 patients treated with LRC for BC and found a PBT rate of 16%. Patients' age, co-morbidities and pathological stage were not related to the PBT rate. A statistically significant relationship was found between the PBT rate and the appearance of infectious complications these findings are explained because of the immuno suppression caused by blood loss and PBT. Overall 3-year survival was significantly worse in the transfused group: 41.38% versus 63.57% for non transfused patients, but PBT was not a significant independent predictor factor in the survival of patients after LRC. The main independent factor was the TNM classification [51]. After these results, efforts should be made in order to limit the use of blood products in patients surgically treated with RC for BC.

## Oncological outcomes

Considering LRC as a novel procedure, it is plausible that ORC might be better in operating time but accumulated experience in LRC may improve this index since the learning curve had already showed a gradual reduction in operating time without compromising the surgical outcomes [54]. Despite significant enthusiasm for LRC in many centres worldwide, a concern remains over pathologic and long-term oncologic results, particularly in patients with more advanced diseases. Regarding pathologic results, LRC might be associated with a lower stage with more organ confined pT2 since no significant difference is obtained in other stages or pathologic grades. Pelvic LND is also an important surgical part of RC. LND not only provides the staging information but is also considered to be curative in patients with nodal metastases.

Herr et al. [55] suggested complete pelvic LND with large numbers of LN yield ensured qualified oncologic outcome. Some authors regarded LN yield as an index of surgical quality with cystectomy [56]. In 2 studies, removal of LN in LRC group was as easy as in the ORC group [57,58], thus there was no statistical significance in the number of LN retrieved between LRC and ORC, however, what is interesting was that LRC group had fewer positive LN yield which might indicate the patients selected in LRC group were associated with less node metastasis.

Dotan et al. [59] demonstrated the impact of positive surgical margins (PSM) on RC outcomes, as their patients with PSM had a disease specific survival rate of 61% at 1 year and 36% at 3 years as well as a median survival of 1.8 years after ORC. They also found that PSM is an independent predictor of metastatic progression in patients undergoing RC, which increased the risk of metastatic progression at 5 years from 32% to 74%. Importantly, none of the patients with organ confined disease had evidence of PSM, suggesting that tumour infiltration may be the main limitation in achieving a negative margin. Among publications on MIBC, 2 LRC series had a 3% and 5% incidence of PSM, and 2 robotic series had a 6% and 10% incidence of PSM, respectively. Although the majority of cases in these 4 studies were reported to be higher stage disease, the limited number of patients in the high risk groups precludes further assumptions [60-63].

The longest mean (median) follow-up reported thus far by any MIRC study is 3 years. Stage for stage, MIRC has comparable short-term and intermediate-term oncologic outcomes to ORC. In the largest single-institutional LRC series, Huang et al. [64] reported oncologic outcomes of 171 patients with a median follow-up of 36 months. Only a third of the patients completed the 5-year follow-up. Mean LN removal was 16 in the whole cohort and 25 in those who underwent an extended pelvic LND (range: 18-46). No patient had PSM. pT3-4 and node-positive diseases were found in 34 and 22%, respectively. Five-year overall, cancer-specific and disease-free survival rates were 74, 81 and 73%, respectively. Another study reported on the oncologic outcomes of 37 LRC patients (54% had ECUD) with mean follow-up of 31 months [60]. Extended pelvic LND was performed in the latter 26 patients (70%), which increased the median LN removal from 6 to 21 nodes. pT3-4 disease was noted in 38% of patients and 19% had positive pelvic LN. Five-year actuarial recurrence-free, cancer-specific and overall survival rates were 92, 92 and 63%, respectively. However, only eight patients completed 5 years of follow-up, while seven patients were either lost to follow-up (n = 2) or had died from unknown causes.

Despite the encouraging early oncologic outcomes by MIRC, ORC remains the current gold standard from an oncologic point of view, since long-term oncologic outcomes are available only for ORC.

## Functional results

The functional outcomes after RC neobladder reconstruction largely determine the patients' post-operative quality of life in terms of urinary continence, which is closely related to post-operative parameters of Qmax, neobladder capacity, intravesical pressure (**IVP**), residual urine volume (**RUV**). There are a few articles comparing post-operative neobladder function after RC between LRC and ORC. A recent meta-analysis included 3 studies, reported daytime continence rates of 91%, 94%, 92% and a night-time rate of 88%, 82%, 78% respectively, and compared favorably with previously reported values in other single LRC series daytime rate (89-98%) and nighttime rate (78-88%) [11,65-67].

## Operating time-Complications-Hospital length of stay

Mean operative time ranged from 4 to 10 hours in the LRC studies and 3.8 to 8.5 hours in the RRC. By comparison a recent large ORC series reported a median hospital stay of 9 days, median blood loss of 1,000 ml and median operative time of 6.4 hours [68]. Complications are one of the most important early end points in the evaluation of patient outcome and surgical technique [68]. Patients undergoing LRC experience significantly fewer overall complications, indicating that LRC might be safer and more effective than those undergoing ORC. One possible explanation of the lower complication rate in LRC is less ASA score, lower EBL, less transfusion requirements and minimally invasive surgery. Minor complications identified statistically significant differences, but not significant for major complications. A comprehensive and meticulous classification of

all complications showed that LRC had a lower incidence of infectious disease (wound infection, pulmonary infection, and systemic sepsis) and ileus [11].

In a review of minimally invasive cystectomy mean hospital stay ranged from 5 to 15 days and from 4 to 11.6 days in the LRC and robotic series [70].

## CONCLUSION

Experience with MIBC compared with ORC has demonstrated that MIBC is safe and feasible, with similar perioperative and pathologic outcomes and improvements in complications rate such as PBT rate. Despite these results, the surgical approach for cystectomy is likely driven by surgeon experience, patient factors, and the best approach to achieve cancer control. Additional information with long-term follow-up data is needed to better understand the important clinical differences between the current available cystectomy approaches for BC.

## References

1. EAU Guidelines. Edn. Presented at the EAU Annual Congress London 2017.
2. Chang SS, Smith JA Jr, Wells N, Peterson M, Kovach B, et al. Estimated blood loss and transfusion requirements of radical cystectomy. *J Urol*. 2001; 166: 2151-2164.
3. Haber G, Crouzet S, Gill I. Laparoscopic and robotic assisted radical cystectomy for bladder cancer: A critical analysis. *Eur Urol*. 2008; 54: 54-62.
4. Parra RO, Andrus CH, Jones JP, Boullier JA. Laparoscopic cystectomy: initial report on a new treatment for the retained bladder. *J Urol*. 1992; 148: 1140-1144.
5. Sanchez de Badajoz E, Gallego JL, Reche A, Gutierrez JM, Jimenez A. Radical cystectomy and laparoscopic ileal conduit. *Arch Esp Urol*. 1993; 46: 621-624.
6. Gill I, Fergany A, Klein E, Kaouk JH, Sung GT, et al. Laparoscopic radical cystoprostatectomy with ileal conduit performed completely intracorporeally: the initial 2 cases. *Urology*. 2000; 56: 26-29.
7. Türk I, Serdar D, Björn W, Bernd S, Loening S. Laparoscopic radical cystectomy with continent urinary diversion (rectal sigmoid pouch) performed completely intracorporeally: the initial 5 cases. *J Urol*. 2001; 165: 1863-1866.
8. Kaufman DS, Shipley WU, Feldman AS. Bladder cancer. *Lancet*. 2009; 374: 239-249.
9. Konety BR, Allareddy V, Herr H. Complications after radical cystectomy: analysis of population-based data. *Urology*. 2006; 68: 58-64.
10. Novara G, De Marco V, Aragona M, Boscolo-Berto R, Cavalleri S, et al. Complications and mortality after radical cystectomy for bladder transitional cell cancer. *J Urol*. 2009; 182: 914-921.
11. Tang, K, Li H, Xia D, Hu Z, Zhuang Q, et al. Laparoscopic versus open radical cystectomy in bladder cancer: a systematic review and meta-analysis of comparative studies. *PLoS One*. 2014; 9: e95667.
12. Stein JP, Lieskovsky G, Cote R, Groshen S, Feng AC, et al. Radical cystectomy in the treatment of invasive bladder cancer: long-term results in 1,054 patients. *J Clin Oncol*. 2001; 19: 666-675.
13. Stein JP, Penson DF, Lee C, Cai J, Miranda G, et al. Long-term oncological outcomes in women undergoing radical cystectomy and orthotopic diversion for bladder cancer. *J Urol*. 2009; 181: 2052-2058.
14. Volkmer BG, Kuefer R, Bartsch GC Jr, Gust K, Hautmann RE. Oncological followup after radical cystectomy for bladder cancer-is there any benefit? *J Urol*. 2009; 181: 1587-1593.
15. Burger, M, Catto JW, Dalbagni G, Grossman HB, Herr H, et al. Epidemiology and risk factors of urothelial bladder cancer. *Eur Urol*. 2013; 63: 234-241.
16. Chavan, S, Bray F, Lortet-Tieulent J, Goodman M, Jemal A. International variations in bladder cancer incidence and mortality. *Eur Urol*. 2014; 66: 59-73.

17. Arumainayagam N, McGrath J, Jefferson KP, Gillatt DA. Introduction of an enhanced recovery protocol for radical cystectomy. *BJU Int.* 2008; 101: 698e701.
18. Patel HRH, Cerantola Y, Valerio M, Persson B, Jichlinski P, et al. Enhanced recovery after surgery: are we ready, and can we afford not to implement these pathways for patients undergoing radical cystectomy? *Eur Urol.* 2014; 65: 263e6.
19. Rivas JG, Gregorio AG, Ledo JC, Orejon RU, Doslada PU, et al. Early recovery protocol in patients undergoing laparoscopic radical cystectomy. *Urological Science.* 2017; 28: 2-5.
20. Cansino JR, Cisneros J, Alonso S, Martínez-Piñeiro L, Aguilera A, et al. Laparoscopic radical cystectomy: initial series and analysis of results. *Eur Urol Suppl.* 2005; 5: 956e61.
21. Fleischmann, A, Thalmann GN, Markwalder R, Studer UE. Extracapsular extension of pelvic lymph node metastases from urothelial carcinoma of the bladder is an independent prognostic factor. *J Clin Oncol.* 2005; 23: 2358.
22. Wright JL, Lin DW, Porter MP. The association between extent of lymphadenectomy and survival among patients with lymph node metastases undergoing radical cystectomy. *Cancer.* 2008; 112: 2401.
23. Studer UE, Collette L. Morbidity from pelvic lymphadenectomy in men undergoing radical prostatectomy. *Eur Urol.* 2006; 50: 887.
24. Thress TM, Cookson MS, Patel S. Robotic Cystectomy with Intracorporeal Urinary Diversion: Review of Current Techniques and Outcomes. *Urol Clin North Am.* 2018; 45: 67-77.
25. Goh AC, Gill IS, Lee DJ, de Castro Abreu AL, Fairey AS, Leslie S, et al. Robotic intracorporeal orthotopic ileal neobladder: replicating open surgical principles. *Eur. Urol.* 2012; 62: 891-901.
26. Guru K, Seixas-Mikelus SA, Hussain A, Blumenfeld AJ, Nyquist J, et al. Robot-assisted intracorporeal ileal conduit: Marionette technique and initial experience at Roswell Park Cancer Institute. *Urology.* 2010; 76: 866-871.
27. Pruthi RS, Nix J, McRackan D, Hickerson A, Nielsen ME. Robotic-assisted laparoscopic intracorporeal urinary diversion. *Eur. Urol.* 2010; 57: 1013-1021.
28. Azzouni F. Current status of robot-assisted radical cystectomy for bladder cancer. *Nat. Rev. Urol.* 2012; 9: 573-582.
29. Alonso y Gregorio S, Alvarez Maestro M, Cabrera Castillo PM, Taberero Gómez A, Cansino Alcaide R, et al. Laparoscopic urinary diversions. *Actas Urol Esp.* 2008; 32: 908-915.
30. Jonsson MN, Adding LC, Hosseini A, Schumacher MC, Volz D, et al. Robot-assisted radical cystectomy with intracorporeal urinary diversion in patients with transitional cell carcinoma of the bladder. *Eur. Urol.* 2011; 60: 1066-1073.
31. Canda AE, Atmaca AF, Altinova S, Akbulut Z, Balbay MD. Robot-assisted nerve-sparing radical cystectomy with bilateral extended pelvic lymph node dissection (**PLND**) and intracorporeal urinary diversion for bladder cancer: initial experience in 27 cases. *BJU Int.* 2012; 110: 434-444.
32. Vallancien G, Abou EF, Cathelineau X, Baumert H, Fromont G, et al. Cystectomy with prostate sparing for bladder cancer in 100 patients: 10-year experience. *J Urol.* 2002; 168: 2413-2417.
33. Botto H, Sebe P, Molinie V, Herve JM, Yonneau L, et al. Prostatic capsule and seminal sparing cystectomy for bladder carcinoma: Initial results for selected patients. *BJU Int.* 2004; 94: 1021-1025.
34. Hautmann RE, Hautmann O, Volkmer BG, Hautmann S. Nerve-sparing Radical Cystectomy: A New Technique. *Eur Urol Suppl.* 2010; 9: 428-432.
35. Rivas JG, Gregorio SA, Gómez ÁT, Alvarez-Maestro M, et al. Laparoscopic radical cystectomy with prostate capsule sparing. Initial experience. *Cent European J Urol.* 2016; 69: 25-31.
36. Kefer JC, Campbell SC. Current status of prostate-sparing cystectomy. *Urol Oncol.* 2008; 26: 486-493.
37. Lee SH, Chang PL, Chen SM, Sun GH, Chen CL, et al. Synchronous primary carcinomas of the bladder and prostate. *Asian J Androl.* 2006; 8: 357-359.
38. Winkler MH, Livni N, Mannion EM, Hrouda D, Christmas T. Characteristic of prostatic incidental adenocarcinoma in contemporary radical cystoprostatectomy specimens. *BJU Int.* 2007; 99: 554-558.
39. Damiano R, Di Lorenzo G, Cantiello F, De Sio M, Perdonà S, D'Armiento M, et al. Clinicopathologic features of prostate adenocarcinoma incidentally discovered at the time of radical cystectomy: an evidence-based analysis. *Eur Urol.* 2007; 52: 648-657.
40. Arroyo C, Andrews H, Rozet F, Cathelineau X, Vallancien G. Laparoscopic Prostate-Sparing Radical Cystectomy: The Montsouris technique and preliminary results. *J Endourol.* 2005; 19: 424-428.
41. Muto G, Collura D, Rosso R, Giacobbe A, Muto GL, et al. Seminal-sparing cystectomy: technical evolution and results over a 20-year period. *Urology.* 2014; 83: 856-861.



42. Mertens LS, Meijer RP, de Vries RR, Nieuwenhuijzen JA, van der Poel HG, et al. Prostate sparing cystectomy for bladder cancer: 20-year single center experience. *J Urol.* 2014; 191: 1250-1255.
43. Fontana PP, Gregorio SA, Rivas JG, Sánchez LC, Ledo JC, et al. Perioperative and survival outcomes of laparoscopic radical cystectomy for bladder cancer in patients over 70 years. *Cent European J Urol.* 2015; 68: 24-29.
44. Aghazadeh MA, Barocas DA, Salem S, Clark PE, Cookson MS, et al. Determining factors for hospital discharge status after radical cystectomy in a large contemporary cohort. *J Urol.* 2011; 185: 85-89.
45. Sietses C, Beelen RH, Meijer S, Cuesta MA. Immunological consequences of laparoscopic surgery, speculations on the cause and clinical implications. *Langenbecks Arch Surg.* 1999; 384: 250-258.
46. Carter JJ, Whelan RL. The immunologic consequences of laparoscopy in oncology. *Surg Oncol Clin N Am.* 2001; 10: 655-677.
47. Shakhbar G, Ben-Eliyahu. Potential prophylactic measures against postoperative immunosuppression: Could they reduce recurrence rates in oncological patients? *Ann Surg Oncol.* 2003; 10: 972-992.
48. Busch OR, Hop WC, Hoyneck van Papendrecht MA, Marquet RL, Jeekel J. Blood transfusions and prognosis in colorectal cancer. *N Engl J Med.* 1993; 328: 1372-1376.
49. Zhou HY, Yi W, Wang J, Zhang J, Wang WJ, et al. Association of perioperative allogeneic blood transfusions and prognosis of patients with gastric cancer after curative gastrectomy. *Am J Surg.* 2014; 208: 80-87.
50. Shiba H, Ishida Y, Wakiyama S, Iida T, Matsumoto M, et al. Negative impact of blood transfusion on recurrence and prognosis of hepatocellular carcinoma after hepatic resection. *J Gastrointest Surg.* 2009; 13: 1636-1642.
51. Rivas JG, Gregorio SA, Ledo JC, Gómez ÁT, Sebastián JD et al. The role of perioperative blood transfusion on postoperative outcomes and overall survival in patients after laparoscopic radical cystectomy. *J Cancer Res Ther.* 2016; 12: 146-149.
52. Linder BJ, Frank I, Chevillat JC, Matthew KT, Thompson RH, et al. The Impact of perioperative blood transfusion on cancer recurrence and survival following radical cystectomy. *Eur Urol.* 2013; 63: 839-845.
53. Morgan TM, Barocas DA, Chang SS, Phillips SE, Salem S, et al. The relationship between perioperative blood transfusion and overall mortality in patients undergoing radical cystectomy for bladder cancer. *Urol Oncol.* 2013; 31: 871-877.
54. Zheng W, Wu X, Zhang L. Laparoscopic radical cystectomy: analysis of a single-surgeon learning curve of 60 cases. *Beijing Da Xue Xue Bao.* 2012; 44: 558-562.
55. Herr HW, Bochner BH, Dalbagni G, Donat SM, Reuter VE, et al. Impact of the number of lymph nodes retrieved on outcome in patients with muscle invasive bladder cancer. *J Urol.* 2002; 167: 1295-1298.
56. Buscarini M, Josephson DY, Stein JP. Lymphadenectomy in bladder cancer: a review. *Urol Int.* 2007; 79: 191-199.
57. Shariat SF, Rink M, Eghdaie B, Xylinas E, Babjuk M, et al. Pathologic nodal staging score for bladder cancer: a decision tool for adjuvant therapy after radical cystectomy. *Eur Urol.* 2013; 63: 371-378.
58. Ghazi A, Zimmermann R, Al-Bodour A, Shefler A, Janetschek G. Optimizing the approach for lymph node dissection during laparoscopic radical cystectomy. *Eur Urol.* 2010; 57: 71-78.
59. Dotan ZA, Kavanagh K, Yossepowitch O, Kaag M, Olgac S, et al. Positive surgical margins in soft tissue following radical cystectomy for bladder cancer and cancer specific survival. *J Urol.* 2007; 178: 2308-2312.
60. Haber GP, Gill IS. Laparoscopic radical cystectomy for cancer: oncological outcomes at up to 5 years. *BJU Int.* 2007; 100: 137-142.
61. Hemal AK, Kolla SB. Comparison of laparoscopic and open radical cystoprostatectomy for localized bladder cancer with 3-year oncological followup: a single surgeon experience. *J Urol.* 2007; 178: 2340-2343.
62. Guru KA, Sternberg K, Wilding GE, Tan W, Butt ZM, et al. The lymph node yield during robot-assisted radical cystectomy. *BJU Int.* 2008; 102: 231-234.
63. Wang GJ, Barocas DA, Raman JD, Scherr DS. Robotic vs open radical cystectomy: prospective comparison of perioperative outcomes and pathological measures of early oncological efficacy. *BJU Int.* 2008; 101: 89-93.
64. Huang J, Lin T, Liu H, Xu K, Zhang C, et al. Laparoscopic radical cystectomy with orthotopic ileal neobladder for bladder cancer: oncologic results of 171 cases with a median 3-year follow-up. *Eur. Urol.* 2010; 58: 442-449.
65. Hautmann RE, Volkmer BG, Schumacher MC, Gschwend JE, Studer UE. Long-term results of standard procedures in urology: the ileal neobladder. *World J Urol.* 2006; 24: 305-314.
66. Kulkarni JN, Pramesh CS, Rathi S, Pantvaideya GH. Long-term results of orthotopic neobladder reconstruction after radical cystectomy. *BJU Int.* 2003; 91: 485-488.

67. Meyer JP, Blick C, Arumainayagam N, Hureley K, Gillatt D, et al. A three-centre experience of orthotopic neobladder reconstruction after radical cystectomy: revisiting the initial experience, and results in 104 patients. *BJU Int.* 2010; 103: 680-683.
68. Shabsigh A, Korets R, Vora KC, Brooks CM, Cronin AM. Defining early morbidity of radical cystectomy for patients with bladder cancer using a standardized reporting methodology. *Eur Urol.* 2009; 55: 164-174.
69. Donat SM. Standards for surgical complication reporting in urologic oncology: time for a change. *Urology.* 2007; 69: 221-225.
70. Hemal AK. Robotic and laparoscopic radical cystectomy in the management of bladder cancer. *Curr Urol Rep.* 2009; 10: 45-54.