

Air in the Kidney

Rohat Ak*, Fatih Doğanay and Özge Ecmel Onur

Department of Emergency Medicine, Fatih Sultan Mehmet Training and Research Hospital, SB University, Turkey

Article Information

Received date: Aug 18, 2017

Accepted date: Aug 21, 2017

Published date: Aug 23, 2017

*Corresponding author

Rohat Ak, Department of Emergency Medicine, Fatih Sultan Mehmet Training and Research Hospital, SB University, E5 Karayolu Üzeri İçerenköy - Ataşehir 34752 İstanbul, Turkey,

Tel: +905068213136;

Email: rohatakmd@gmail.com

Distributed under Creative Commons CC-BY 4.0

What is your Diagnosis?

A 55-year-old woman admitted to our emergency department with three days history of abdominal pain, fever and vomiting. She was a known diabetic patient for last 25 years. On admission, she had fever (39°C), heart rate of 100BPM and a normal blood pressure and respiratory rate. The physical examination revealed an ill-looking patient with distended abdomen. There was extremely tender right renal angle with a diffusely tender right loin. The laboratory support showed leukocytosis, creatinine 2.06mg/dl and random serum glucose 512mg/dl. Urinalysis revealed numerous pus cell an RBC but ketonuria was absent. The cultures from the blood and urine sample showed *Escherichia coli* organism. Abdomen CT showed gas into the renal parenchyma and into the perirenal space on the right (Figures 1,2). The patient was diagnosed Emphysematous Pyelonephritis and successfully treated with antibiotic and supportive therapy. EPN is a uniformly fatal illness, if left untreated [1]. Treatment should be aggressive, starts with vigorous fluid resuscitation, antibiotic therapy, and control of blood sugar and electrolytes [2,3]. Before the advent of interventional radiology, early surgery and nephrectomy was a mandatory procedure.

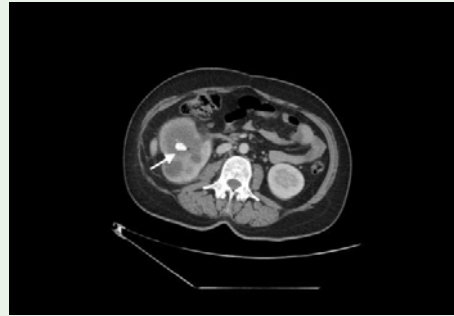


Figure 1: The abdominal computed tomography shows gas into right the renal parenchyma and a renal calculi (arrow).

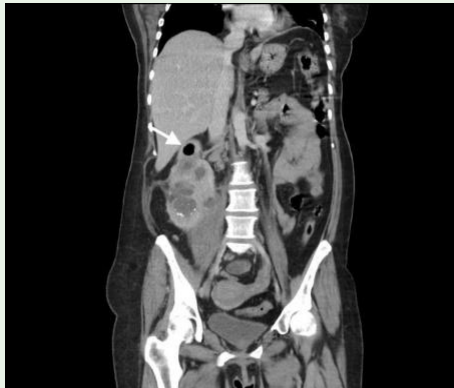

Figure 2: A coronal view of abdominal computed tomography shows an enlarged right-kidney and peri-renal gas (arrow).

References

1. Ubee SS, Mc Glynn L, Fordham M. Emphysematous pyelonephritis. *BJU Int.* 2011; 107: 1474-478.
2. Karasavidou L, Nikolaou S, Archontakis S, Papatheodorou G, Koroneos V, Drakoulis C. Nonsurgical treatment of bilateral Emphysematous pyelonephritis in a diabetic patient. *J Nephrol.* 2006; 19: 664-667.
3. Huang JJ, Tseng CC. Emphysematous pyelonephritis: Clinicoradiological classification, management, prognosis, and pathogenesis. *ArchInternMed.* 2000; 160: 797-805.