

Post Abdomino-Perineal Resection Urethrocutaneous Fistula: A Rare Cause of Persistent Perineal Sinus and its Minimal Invasive Technique of Management

Sandeep Nunia, Priyank Yadav, Prempal Singh, Devarshi Srivastava, Ankur Bansal and Aneesh Srivastava*

Department of Urology and Renal Transplant, Sanjay Gandhi Postgraduate Institute of Medical Sciences, India

Article Information

Received date: Mar 18, 2017

Accepted date: May 30, 2017

Published date: May 31, 2017

*Corresponding author

Aneesh Srivastava, Professor and Head, Department of Urology and Renal Transplant, Sanjay Gandhi Postgraduate Institute of Medical Sciences, Lucknow, 226014, India, Tel: +91-8004904824, +91-9415011093; Email: aneesh892012@gmail.com

Distributed under Creative Commons CC-BY 4.0

Keywords Urethro-cutaneous fistula; Retrograde urethrography; Abdomino perineal resection

Abstract

Persistent perineal sinus is a common complication after perineal surgeries reporting upto 30% in various series. Most common underlying cause is wound infection, lymphocele, incomplete healing due to irradiated tissue etc. Iatrogenic urethral injury leading to urethro-cutaneous fistula is a rarely reported cause of perineal sinus. Most of the cases of perineal sinuses are usually neglected, considering them for spontaneous healing. Here we have reported a case incorporating the clinical presentation, diagnostic difficulty and a minimal invasive modality for successful management of this distressing condition.

Introduction

Most common cause of urethral injury after anorectal surgery is traumatic catheterization. Rare cases of urethral injuries had been reported in the literature after anorectal surgeries especially in certain circumstances like locally advanced disease, Crohn's disease, post radiotherapy, intra operative injury due to energy devices. Intra operative recognition of these injuries is rare due to continuous decompression of urinary system by indwelling catheter. Duration and presentation of urethral injury is quite variable like paralytic ileus, urinoma formation, perineal phlegmon, and urethrovaginal fistula in females. Persistent perineal sinus is a common complication of Abdomino Perineal Resection (APR), but mainly its underlying cause is persistent lymphocele. Urethro-Cutaneous Fistula (UCF) presenting as a cause of refractory non-healing perineal sinus is rarely reported. Although a plenty of conservative measures have been described but we have described a minimal invasive technique for dealing the UCF in primitive phase, with minimal morbidity.

Case History

53 yrs old male presented with history of altered bowel habits for a duration of 1 ½ yrs. He also complained of melena 1-2 episodes/ month, mixed with stools. No h/o fever with chills, jaundice, pruritus, bony pains, cough with expectoration. He was evaluated for the above symptoms with CECT abdomen and pelvis that revealed a growth in the lower rectum with peri-rectal fat stranding (Figure 1A), mesorectal lymph nodes present, no ascites, and no liver lesion. MRI abdomen -pelvis showed 14cm long circumferential irregular growth in rectum starting at 4cm from the anal verge, mass infiltrating the peri rectal fat at multiple points, involves mesorectal fascia, anorectal junction and upper part of internal anal sphincter and found to have cT3N1M0 and was given neoadjuvant chemotherapy and radiotherapy. Patient received a total of 50gy/28# @1.8gy/#, along with oral Capecitabine. He underwent Laparoscopic APR on selective basis after 6 weeks. On laparoscopy, no evidence of dissemination in the form of liver/omental/peritoneal or serosal nodules was found. Rectum mobilised in pelvis till the level of levator anti posteriorly and prostate anteriorly-TME (total mesorectal excision) done. Perineal dissection done, started about 1.5 cm from anal verge circumferentially and exterior to external sphincter, joined the dissection done intra-abdominally. Specimen was delivered through perineal route.

Postoperative course was uneventful and Per-Urethral Catheter (PUC) was removed on POD 7 and patient could not pass urine for which PUC was reinserted. On POD 10, he complained of some soakage in perineum. On examination there was a perineal sinus in between anal dimple and scrotal base (Figure 1B). Conservative treatment was offered to the patient with perineal hygiene.

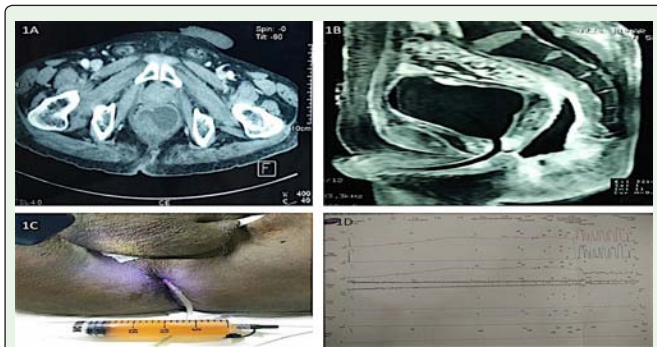


Figure 1: A) CECT showing an irregular surfaced intra luminal anorectal growth arising from right posterolateral wall. B) T2 weighted MRI in sagittal section showing a fistulous communication arising from proximal urethra. C) Location of perineal sinus and urine mixed with lymph drained by calibrating with Ryle's tube. D) UDS curve showing underactive detrusor secondary to neural damage.

USG pelvis was done which showed a residual collection measuring 80 ml in retrovesical region.

For lower urinary tract evaluation, urodynamic study was done which showed underactive detrusor with normal capacity and poor compliance (Figure 1C). Patient was kept on Clean Intermittent Catheterisation (CIC) and followed in OPD for spontaneous recovery of bladder and closure of perineal sinus. Even after 2 months of conservative treatment when the sinus remained patent then MRI pelvis was done which showed a fistulous connection arising from proximal urethra upto perineal sinus with a small collection in retrovesical space (Figure 1D). RGU-MCU was done to confirm the findings that clearly delineate the sinus tract (Figure 2A).

When the urethrocutaneous fistula was found to be the cause of persistent non healing perineal sinus, all the treatment approaches and their limitations was discussed with the patient and he opted for minimal invasive approach, so SPC was done for complete diversion and perineal sinus was cannulated by 14 Fr R.T. and 0.2% betadine solution was used as sclerosant for 2 weeks to obliterate the cavity. Patient was reviewed in OPD after 6 weeks. SPC was removed and kept on CIC (underactive detrusor) for 6 weeks. Patient resumed normal voiding behavior and RGU-MCU revealed complete healing of fistulous communication with mild diverticular projection in proximal urethra with a small puckering or scarred dimple at previous sinus at perineum with no discharge in sinus (Figure 2B).

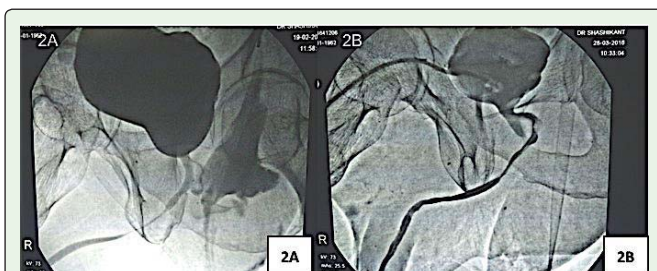


Figure 2: A) MCU showing complete urethro-cutaneous fistula before intervention. B) MCU showing complete healing of fistula with slight residual projection of sinus tract.

Discussion

Persistent perineal sinus is a distressing condition due to malodorous fluid draining from perineum, having high social stigmata. Most of the cases are iatrogenic, secondary to APR, total proctocolectomy, pelvic exenteration etc. [1]. Pathophysiology described for perineal sinus is that the dead space created by removal of pelvic viscera is replaced by blood and lymph, which get secondarily infected and ultimately develop a path of least resistance for spontaneous drainage in the perineum. Once the sinus is developed, due to persistent lymphatic output after extensive dissection and poor healing power of irradiated tissue, these perineal wounds are notorious to get healed. Most of the patients needed rotational flaps for durable outcome, once the output is reduced.

Due to extensive dissection in pelvis and disruption in neurovascular integrity of bladder, voiding dysfunction is reported in as many as 70 % cases, but most of them didn't require any active intervention except indwelling catheterization for couple of weeks. Detrusor under activity seen in UDS is temporary, and showed good spontaneous recovery, if gross breach in endopelvic fascia, leading to disruption of parasympathetic supply of bladder had not occur intra-operatively.

Urethral injury had been reported in locally advanced malignancies involving ventral aspect of prostate. Most of the cases of perineal sinus manifest within a week of surgery. In this clinical scenario, the patient has indwelling catheter for more than 6 weeks, and condition manifests after catheter removal, but if the patient has already persistent sinus then the condition remain unidentified, as increase in soakage after PUC removal is not easily appreciable. If patients with underactive detrusor are kept on CIC, then also the condition remain uncovered, and condition manifests once the spontaneous voiding resumes. Delayed presentation, diagnostic dilemma, refractory to management is the most annoying aspects of this condition for the treating surgeon. Early identification of such rare complications is paramount for reducing morbidity of these patients and reducing social dilemma.

Various conservative measures like broad-spectrum antibiotics, instillation of fibrin glue [2] in sinus, use of hyperbaric oxygen [3], topical application of metronidazole ointment [4] had been described in literature with various success rates. Betadine 0.2% had been used in lymphocele with variable success rates. Here we have used 0.2% betadine sclerosant for obliteration of urinoma cavity with adequate diversion, showing good results.

References

1. Christian CK, Kwaan MR, Betensky RA, Elizabeth MB, Michael JZ, Ronald Bleday. Risk factors for perineal wound complications following abdominoperineal resection. *Dis Colon Rectum*. 2005; 48: 43-48.
2. Zmora O, Mizrahi N, Rotholtz N, Alon JP, Eric GW, Juan JN, et al. Fibrin glue sealing in the treatment of perineal fistulas. *Dis Colon Rectum*. 2003; 46: 584-589.
3. Capelli-Schellpfeffer M, Gerber GS. The use of hyperbaric oxygen in urology. *J Urol*. 1999; 162: 647-654.
4. Maeda Y, Lohsiriwat V et al. Effects of topical administration of 10% metronidazole ointment on longstanding persistent perineal sinus: a pilot study. *Colorectal Dis*. 2007; 9: 55.