

Chylous Clot Removal Using  
Morecellator: A Novel MethodAnkur Bansal<sup>1\*</sup>, Ankur Jhanwar<sup>1</sup>, Gaurav Prakash<sup>1</sup> and Satyanarayan Sankhwar<sup>1</sup><sup>1</sup>King George Medical University, Uttar Pradesh, India

## Article Information

Received date: Dec 23, 2016

Accepted date: Jan 18, 2017

Published date: Jan 20, 2016

## \*Corresponding author

Ankur Bansal, King George Medical  
University, Uttar Pradesh, India,  
Email: ankurbansaldmc@gmail.comDistributed under Creative Commons  
CC-BY 4.0Keywords Chylous clot; Morecellator;  
Chyluria

## Abstract

We report a novel method of chylous clot removal using morcellator where other conventional methods fail. A 22-year male with recurrent chyluria presented in acute urinary retention. Clot evacuation using Toomey syringe, ellik evacuator and suction bridge have failed. Based on our use of morcellator (versa cut tissue morcellator, lumenis) during HoLeP procedure, we applied this morcellator to morcellate large and tenacious chylous clot. We successfully removed the clot using morcellator with suction (versa cut tissue morcellator, lumenis) used for morcellating prostate adenoma tissue in Holmium Laser Enucleation of Prostate (HoLeP).

## Introduction

Chyluria is passage of chyle in the urine due to abnormal communication between intestinal lymphatics and urinary tract causing intermittent discharge of chyle from intestinal lymphatic into renal pelvis. Common urological presentation is in the form of passage of milky-white urine, Chylo-Hematuria and rarely, acute urinary retention due to clots. Methods of clot evacuation include Ellik evacuator, Toomey syringe and suction bridge [1]. Rarely, open cystotomy is required for patients where conventional methods fail. We report a novel method of clot evacuation using morcellator thus avoiding open cystotomy.

## Case Report

A 22-year old male, a known case of recurrent chyluria, presented with acute urinary retention. Abdominal ultrasound revealed a large clot in urinary bladder with normal upper tracts (Figure 1). Emergent cystoscopic examination revealed a large and tenacious chylous clot in the bladder (Figure 2) and efflux of chyle from the left ureteric orifice with clear-urinary efflux from the right side. Clot removal was attempted with Ellik evacuator, Toomey syringe and mechanical suction using suction bridge. However, these procedures failed to remove clots due to the elasticity and large size of clot. Morcellation and suction (Versa Cuttissue morcellator, Lumenis) was performed with morcellator used for morcellating prostatic adenoma tissue in holmium laser enucleation of prostate (HoLeP) procedure to evacuate the clot (Figure 3). 160 ml clots were removed in 18 minutes. The integrity of the urinary bladder was ensured. Post procedure, bladder irrigation through 22-Fr Foley catheter (triway) was initiated and post-operative period was uneventful. Foley catheter was removed after 48hrs. Later the patient was managed with sclerotherapy using 0.2% Povidine iodine on the left side [2].

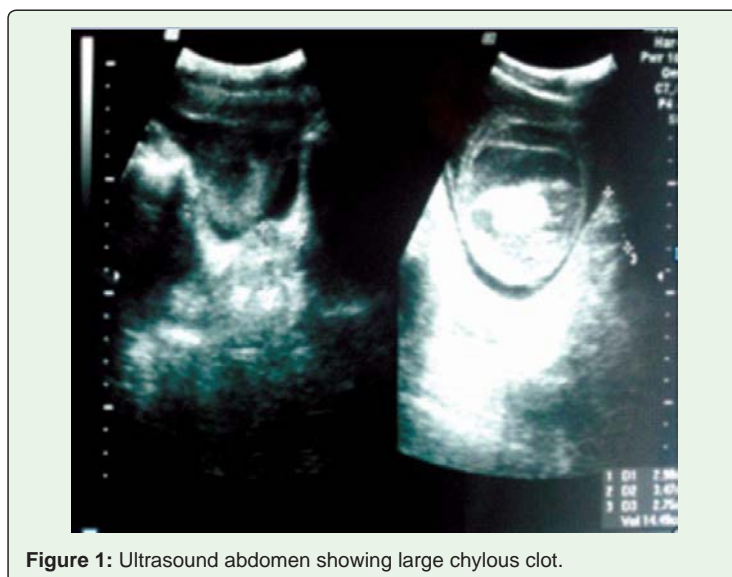

Figure 1: Ultrasound abdomen showing large chylous clot.

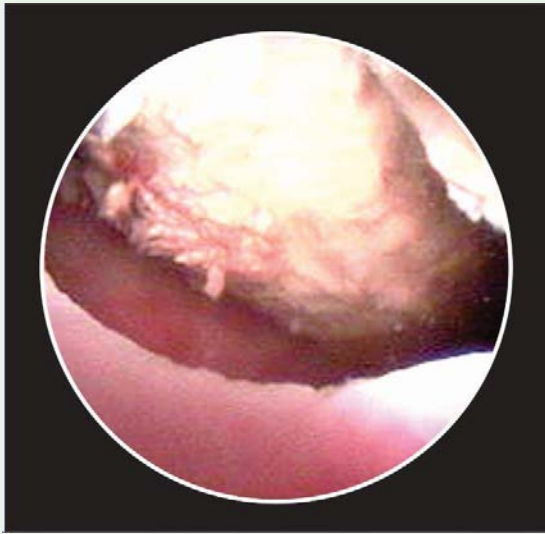

Figure 2: Cystoscopic view of large chylous clot.

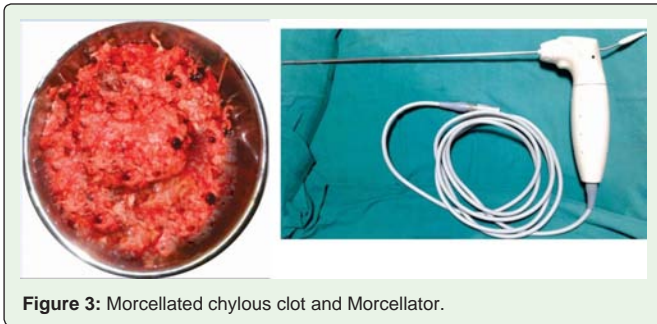


Figure 3: Morcellated chylous clot and Morcellator.

## Discussion

Large blood and chylous clots can cause urinary retention. In most cases, clot evacuation with Ellik evacuator or Toomey syringe is effective. But, sometimes pressures generated by these methods are not enough to remove large and tenacious clot and may cause bladder injury. To avoid open cystectomy for the removal of large and tenacious clots, various non-surgical treatments are described. Bo et al in their study mentioned the use of 40,000 U of chymo-trypsin in 50 ml of 5% sodium bicarbonate for blood clot removal [3]. Ritch

et al described the use of alteplase (tissue plasminogen activator) for dissolving blood clots [4]. Goel et al described the use of mechanical suction for safe removal of large and tenacious clots from the urinary bladder [5]. But the effectiveness of these methods for removing chylous clot is not known. Minimally-invasive method of chylous clot removal has not been mentioned in literature due to rarity of this disease in western population. Morcellation of Prostatic Adenoma is needed after transurethral HoLEP. It has a combination of tissue morcellator and suction. We used this method for clot removal in our patient thus avoiding open cystectomy. Although, gaining popularity, HoLEP is not available in all urology centers. We suggest the use of morcellator (versa cut tissue morcellator) in patients with clot retention where other methods fail. As morcellation is done under vision there are fewer chances of complications like perforation and Hematuria. It is also faster and more effective. Although, we have used this method for removal of chylous clots but morcellator should be effective for removal of large blood clots also. To the best of our knowledge this is the only report in the literature where large and tenacious chylous clots have been removed using morcellator with suction (versa cut tissue morcellator) (Figure 3).

## Conclusion

Clot evacuation using morcellator is safe and feasible approach and should be kept in mind where other methods have failed. However, it can be used only by surgeons who have experience with this method.

## References

1. Goel A, Dalela D. Mechanical suction for clot evacuation: experience with "suction bridge" for safe and effective clot removal. *Int Urol Nephrol*. 2015; 47: 723-726.
2. Goel S, Mandhani A, Srivastava A, Kapoor R, Gogoi S, Kumar A, et al. Is povidone iodine an alternative to silver nitrate for renal pelvic instillation sclerotherapy in chyluria? *BJU Int*. 2004; 94: 1082-1085.
3. Bo J, Yangyang Y, Jiayuan L, Siwen D, Yong C, Junbo Y, et al. Evaluation of bladder clots using a nonsurgical treatment. *Urology*. 2014; 83: 498-499.
4. Ritch CR, Ordonez MA, Okhunov Z, Araujo J, Walsh R, Baudin V, et al. Pilot study of Alteplase (tissue plasminogen activator) for treatment of urinary clot retention in an *in vitro* model. *J Endourol*. 2009; 23: 1353-1357.
5. Goel A, Sengottayan VK, Dwivedi AK. Mechanical suction: an effective and safe method to remove large and tenacious clots from the urinary bladder. *Urology*. 2011; 77: 494-496.