

Refining Techniques in Eyebrow
Transplantation

Anthony Bared* and Jeffrey S. Epstein

Private practice, Sunset Drive, Miami, USA

Article Information

Received date: Mar 16, 2017

Accepted date: Apr 21, 2017

Published date: Apr 24, 2017

*Corresponding author

Anthony Bared, Private practice, Sunset Drive, Miami, USA, Tel: (305) 666-1774; Email: abmd@fhrps.com

Distributed under Creative Commons CC-BY 4.0

Abstract

There has been a growing demand for facial hair restoration including eyebrow hair transplantation. The demand for non-scalp hair restoration is reflective of the cultural trends where full eyebrows are in vogue. Our clinic has seen a large increase in non-scalp hair restoration. Given the large experience allowed by our patient population, we have been able to refine our techniques for optimal results in eyebrow restoration. Presented in this article are our techniques developed from over 1,000 eyebrow transplantations.

Introduction

Pick up any recent magazine and you will see it filled with models with thick, full eyebrows. Gone are the pencil thin-eyebrows popularized in the past. The latest vogue is for full, thick eyebrows. Many patients with naturally thin eyebrows or thinning eyebrows due to over-plucking/ aging are now being seen in our clinic desiring to have fuller eyebrows. Cultural trends and refinements in hair transplantation techniques, as well as the results we are achieving, have resulted in a huge increase in the number of patients seen for eyebrow transplantation. This article describes the clinical evaluation and candidacy for eyebrow transplantation, the Surgical Techniques, The Post-Operative Care, And the Management of Complications.

Pre-Operative Evaluation

Patients seen for eyebrow transplantation have either absent eyebrows, thin eyebrows, or want to fill in a scar within the eyebrows. Patients can have thin eyebrows for a number of reasons which have to all be considered: genetically thin eyebrows, medical history such as thyroid disorders, various types of alopecia, aging, medication use, and iatrogenic from over-plucking are the most common causes. Note that cases of alopecia areata/totalis are usually not effectively treated with hair transplants, so this must be ruled out before considering surgery [1,2]. In women, the most common cause we see in our clinic for patients considering eyebrow transplantation is iatrogenic from over plucking. Men typically lose the lateral aspect of the eyebrows with aging and are seeking overall thicker eyebrows [3]. A thorough history and physical examination focusing on hair loss needs to be performed for any patient considering eyebrow hair restoration.

Most commonly the occipital scalp donor hair is the best donor hair for eyebrow transplantation because of its most reliable growth. Although other areas can be used as donor hair, the regrowth is typically not as reliable and sometimes there is insufficient supply. We use the Follicular Unit Extraction (FUE) as well as the more traditional strip/Follicular Unit Grafting (FUG) technique equally for obtaining the donor hairs. In men, FUE is more often the chosen technique due to the possibility of the patient wanting to cut his hair short and not have to worry about any linear donor site scar [4]. For patients particularly women who plan on keeping a longer hairstyle, we prefer FUG for donor harvesting as it allows the hair in the harvested follicular units to remain longer allowing for the visualization of the natural curl of the hair when planting the grafts. The donor hair is evaluated for both its quality and quantity. Thick and straight hair provides a challenge in that care must be taken to have the hair lie as flat as possible during the transplantation procedure.

As with any cosmetic procedure, it is important to set proper expectations. During the consultation patients are counseled in that the goal of transplantation is for fuller, thicker eyebrows and not 'perfectly' shaped eyebrows. They are explained that the advantage of a hair transplantation procedure is that the results are natural in appearance. Unlike tattooing/ permanent makeup, the shape of the eyebrows can always be altered in the future if so desired. Patients are also made to understand that if the transplanted grafts are depilated enough, they will cease to grow. They are given clear expectations as to the expected swelling after the procedure and the recovery.

Operative Planning

The goal in eyebrow restoration is to restore the desired shape, density, natural direction and angle of growth of eyebrow hair. Patients are encouraged to bring in photos of their "ideal" or model eyebrows. Pre-operative photos are then obtained. The patient is asked to both open and

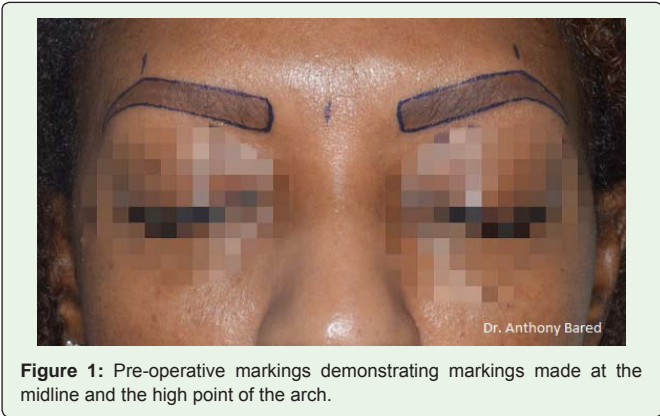


Figure 1: Pre-operative markings demonstrating markings made at the midline and the high point of the arch.

close their eyes while photos are taken. Photos are taken from the frontal view of both eyebrows then a three quarter view of each eyebrow. The camera acts as a ‘third eye’ helping to pick up subtle asymmetries. It is often found that eyebrow elevation is asymmetric as there tends to be an asymmetric elevation of the eyebrows by the facial musculature and sometimes that associated with asymmetry of the eyelids. These asymmetries are noted and also made known to the patients. Once pre-operative photos are obtained, patients who like how they draw in their eyebrows are seated in front of a mirror in the pre-operative suite and given an eye-liner pen. The majority of our female patients are able to draw in their desired eyebrows, which we encourage, but then often require some fine-tuning by the surgeon (Figure 1). It is helpful for the patient to take the time to draw in the desired shape of their eyebrows. Once preliminary drawings are made by the patient, the surgeon then fine tunes the shape. Measurements are taken along the length and in various places along the width of the eyebrows to ensure as much symmetry as possible. The midline is marked and measurements off the midline are also taken. As many natural eyebrows are inherently asymmetric, some minor degree of discrepancy is tolerated between the two sides. The final shape is then shown to the patient and photos of this shape are taken in a similar fashion to the pre-marking photos. If occipital hair is to be harvested in the strip method, the donor hair is then trimmed leaving the hair initially at least 1 cm in length for planting. Maintaining the donor hair on the harvested strip at least 1 cm allows for the preservation of the natural curl of the eyebrow to be seen when planted, ensuring the grafts are planted in such a manner that the direction of growth would be acutely towards the skin. This is a bit more challenging

when performed via the follicular unit extraction technique but is not a reason not to use FUE for these procedures. Patients are typically offered light oral sedation for the procedure.

Operative Procedure

The donor area is anesthetized with local anesthesia composed of lidocaine 2%/ 1:100,000 epinephrine. A calculation of the size of the strip excision is then made based on the number of grafts needed and the donor hair density. The strip typically varies in length and width from about 3 to 6 cm and 10 to 15 mm, respectively. The patient is maintained in the seated position for strip harvesting. If follicular unit extractions are performed then the patient is placed in the prone position. Given the relatively small number of grafts needed for eyebrow transplantation, usually ‘tunnels’ can be made at various places where the hairs are trimmed short for extraction, allowing the surrounding hair to be maintained long.

Once the donor hairs have been harvested, the patient is then placed in a seated, reclined position for incision site placement. The eyebrow area is anesthetized with local anesthesia containing epinephrine for hemostasis. After adequate time has been allowed for the local anesthesia to take effect, the recipient sites are made using the smallest blade size for the graft-typically 0.5 mm or 0.6 mm. Initial recipient sites are made along the periphery along the pre-marked borders of the eyebrows. It is important to start with these peripheral marking incisions as the pre-operative markings can soon be lost with the subsequent bleeding and wiping. Incisions are made in an acute angle as possible to the skin (Figure 2). Proper direction of hair growth is critical. Within the head (medial-most aspect) of the eyebrow inferiorly the hairs usually grow in a superior and slightly lateral direction. As one moves more superior within the head of the eyebrow the direction changes to a more lateral then inferior direction. As one then moves more laterally into the body (mid-portion), the hairs grow in an inferior-lateral direction along the superior border and in a superior-lateral direction along the inferior border. Within this body, which constitutes the majority of the eyebrow, this crossed-hatch pattern achieves the greatest amount of density. Then, the lateral-most one-quarter or so of the eyebrow, called the tail, has horizontally-oriented recipient sites.

Once all incision sites are made, the grafts are then inserted. A typical procedure can range from 150 to as many as 400 grafts per eyebrow, depending on a variety of factors. The grafts are placed so that

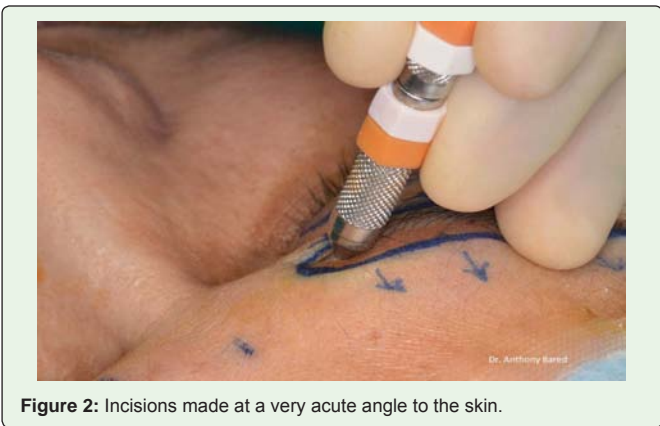

Figure 2: Incisions made at a very acute angle to the skin.

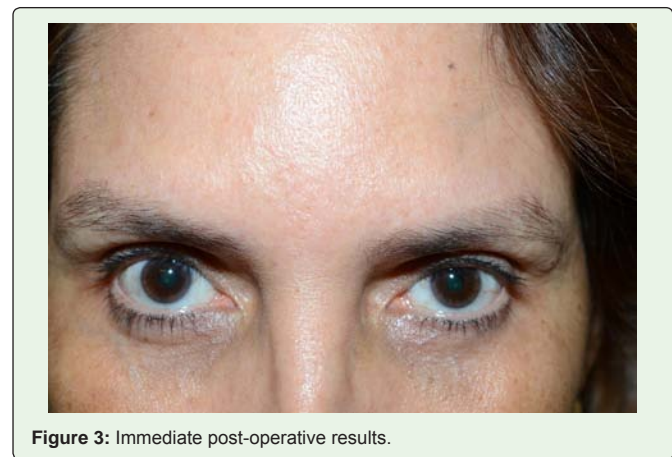

Figure 3: Immediate post-operative results.

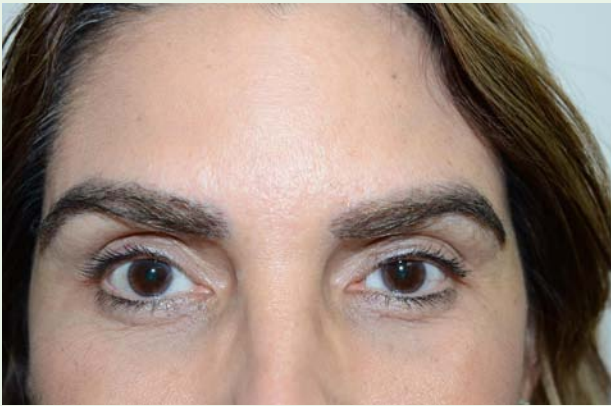

Figure 4: One year post-operative results of the same patient.

the direction of the hair growth, that is the curl of the hair, is placed in as an acute angle as possible with the skin. In most cases, as many 2-hair grafts as possible are placed within the eyebrows, primarily the central portion but also in parts of the head and tail. Only those 2-hair grafts where the hairs are seen growing in the same direction are used. 2-hair grafts are not utilized if the hairs are divergent in their growth. We have found that the use of as many 2-hair grafts as possible creates the most amount of density within the eyebrows. Mostly 1-hairs grafts are used along the borders, periphery and tail region. After all the grafts are placed, the patient is asked to sit up and the eyebrows are inspected. Additional grafts are then placed if small adjustments are deemed appropriate. The patient is then shown the eyebrows in a mirror for their feedback as well (Figures 3 and 4).

Post-Operative Care

Patients are instructed to maintain the eyebrow area dry for 5 days. The scalp hair may be washed the first post-operative day. Antibiotic ointment is applied to the donor area twice daily for one week. If the strip method was utilized for donor site harvesting, the sutures are removed around the 10th post-operative day, or can be expected to dissolve in 3 weeks. Antibiotics and pain medications are given for the first several days. Patients are allowed to use makeup in the eyebrow area after all the crusts have fallen out at typically five days. The planted grafts will start to fall out around 2 to 3 weeks after the procedure and the eyebrows return to their pre-procedure form. On average the grafts will start to regrow in around 4 to 6 months with final results noted around 10 months to 1 year. After the initial immediate follow-up period, patient's follow-up at 10 months to assess results.

Complications and Their Management

Asymmetry

One of the most common complications seen is asymmetry of the eyebrows. Although a slight degree of asymmetry is expected, the eyebrows are made to appear as symmetric as possible. It is critical that when marking the eyebrow symmetry is checked and re-

checked. Differences on forehead animation are noted. As describes previously, the eyebrows are analyzed with both the eyes open and closed. It is helpful to avoid re-injecting of the local anesthetic during the procedure until after all the grafts have been planted and the patient is asked to sit up for analysis. Repeated injection of the local anesthetic and localized swelling can create a pseudo-asymmetry of the eyebrows during the procedure which is this avoided.

Lower than expected density

Another potential complication is that of density less than expected. This is sometimes due to lower than expected rates of hair regrowth, but more commonly due to unrealistic expectations, thus patients need to be advised that the result will be a significant improvement but that perfectly full eyebrows are not usually realistic. Given the small area and the overall small amount of grafts, a reduction in regrowth can occur with eyebrow transplantation. Most patients are advised that a smaller, secondary procedure may be warranted after 1 year to help further fill in the eyebrows- this is occurring less and less frequently as we have developed better and better techniques, to where this is requested in less than 15% of our patients.

Less than ideal angulation

Less than ideal angulation may occur in some grafts despite the efforts to place the grafts in an acute an angle as possible with the skin. This is most likely secondary to the effects of wound contracture around the transplanted grafts. It is most commonly seen in patients with coarse, thick, straight hair. This complication is best avoided by not trimming the donor hairs too short to allow for the visualization of the natural curl of the hair, and keeping the recipient sites as small as possible to minimize the micromigration that can occur. When the grafts are placed, they should be rotated so that the direction of hair growth is acute to the skin. If this misdirection is problematic— something we usually see in cases referred to us for repairs— these aberrant grafts can be removed via follicular unit extraction. In most mild to moderate cases measures can be taken to manage these grafts with a variety of products available to help train the misdirected hairs.

Concluding Remarks

It is remarkable how the eyebrows truly do 'frame the face.' Eyebrow transplantation has a high level of patient satisfaction. It is a challenging yet very rewarding procedure for both its artistic and technical demands for the hair restoration surgeon.

References

1. Rogers N. Imposters of androgenetic alopecia: diagnostic pearls for the hair restoration surgeon. *Facial Plast Surg Clin N Am*. 2013; 21: 325-334.
2. Tosti A, Piraccini BM. *Diagnosis and treatment of hair disorders: an evidence based atlas*. New York: Informa Healthcare. 2005.
3. Epstein JS. Hair restoration to eyebrows, beard, sideburns, and eyelashes. *Facial Plast Surg Clin N Am* 2013; 21: 457-467.
4. Rassman WR, Berstein RM, McClellan R, Jones R, Worton E, Uyttendaele H. Follicular unit extraction: minimally invasive surgery for hair transplantation. *Dermatol Surg*. 2002; 28: 720-728.